



National
Comprehensive
Cancer
Network®

NCCN Clinical Practice Guidelines in Oncology™

Central Nervous System Cancers

V.1.2009

Continue

www.nccn.org

NCCN Central Nervous System Cancers Panel Members

* Steven S. Brem, MD/Chair ¶
H. Lee Moffitt Cancer Center
and Research Institute

Philip J. Bierman, MD † ‡
UNMC Eppley Cancer Center
at The Nebraska Medical Center

Peter Black, MD, PhD ¶
Dana-Farber/Brigham and Women's Cancer Center

Henry Brem, MD ¶
The Sidney Kimmel Comprehensive
Cancer Center at Johns Hopkins

Marc C. Chamberlain, MD Ψ
Fred Hutchinson Cancer Research
Center/University of Washington

Ennio A. Chiocca, MD, PhD ¶
Arthur G. James Cancer Hospital
& Richard J. Solove Research Institute
at The Ohio State University

Lisa M. DeAngelis, MD Ψ
Memorial Sloan-Kettering Cancer Center

Robert A. Fenstermaker, MD ¶
Roswell Park Cancer Institute

Allan Friedman, MD ¶
Duke Comprehensive Cancer Center

Mark R. Gilbert, MD Ψ
The University of Texas
M. D. Anderson Cancer Center

Stuart A. Grossman, MD † Ψ
The Sidney Kimmel Comprehensive
Cancer Center at Johns Hopkins

Amy B. Heimberger, MD ¶
The University of Texas
M. D. Anderson Cancer Center

Deneen Hesser, RN, BS, OCN
American Brain Tumor Association

Larry Junck, MD Ψ
University of Michigan
Comprehensive Cancer Center

Gerald P. Linette, MD, PhD †
Siteman Cancer Center at Barnes-Jewish
Hospital and Washington University
School of Medicine

Jay S. Loeffler, MD §
Dana-Farber/Brigham and Women's Cancer
Center | Massachusetts General Hospital
Cancer Center

Moshe H. Maor, MD §
The University of Texas
M. D. Anderson Cancer Center

Paul L. Moots, MD Ψ
Vanderbilt-Ingram Cancer Center

Tara Morrison, MD Ψ
Fox Chase Cancer Center

Maciej M. Mrugala, MD, PhD, MPH Ψ
Fred Hutchinson Cancer Research
Center/University of Washington

* Louis Burt Nabors, MD Ψ
University of Alabama at Birmingham
Comprehensive Cancer Center

Herbert B. Newton, MD Ψ
Arthur G. James Cancer Hospital
& Richard J. Solove Research
Institute at The Ohio State University

Alessandro Olivi, MD ¶
The Sidney Kimmel Comprehensive
Cancer Center at Johns Hopkins

Jana Portnow, MD † Ψ
City of Hope

Michael Prados, MD Ψ
UCSF Helen Diller Family
Comprehensive Cancer Center

* Jeffrey J. Raizer, MD Ψ
Robert H. Lurie Comprehensive Cancer
Center of Northwestern University

Lawrence Recht, MD Ψ
Stanford Comprehensive Cancer Center

Dennis C. Shrieve, MD, PhD §
Huntsman Cancer Institute
at the University of Utah

Allen K. Sills, Jr., MD ¶
St. Jude Children's Research
Hospital/University of Tennessee
Cancer Institute

Frank D. Vrionis, MD, MPH, PhD ¶
H. Lee Moffitt Cancer Center
and Research Institute

Continue

† Medical oncology
‡ Hematology/Hematology oncology
§ Radiotherapy/Radiation oncology
Ψ Neurology/neuro-oncology
¶ Surgery/Surgical oncology
* Writing committee member

[NCCN Guidelines Panel Disclosures](#)

NCCN 2009 Central Nervous System Cancers Sub-Committee Members

Principles of Imaging

Jeffrey J. Raizer, MD/Lead Ψ
Robert H. Lurie Comprehensive
Cancer Center of Northwestern University

Steven S. Brem, MD ¶
H. Lee Moffitt Cancer Center
and Research Institute

Larry Junck, MD Ψ
University of Michigan
Comprehensive Cancer Center

Louis Burt Nabors, MD Ψ
University of Alabama at Birmingham
Comprehensive Cancer Center

PCNSL Review

Maciej Mrugala, MD, PhD, MPH/Lead Ψ
Fred Hutchinson Cancer Research
Center/University of Washington

Philip J. Bierman, MD † ‡
UNMC Eppley Cancer Center
at The Nebraska Medical Center

Lisa M. DeAngelis, MD Ψ
Memorial Sloan-Kettering Cancer Center

Principles of Systemic Therapy

Louis Burt Nabors, MD/Lead Ψ
University of Alabama at Birmingham
Comprehensive Cancer Center

Marc C. Chamberlain, MD Ψ
Fred Hutchinson Cancer Research
Center/University of Washington

Larry Junck, MD Ψ
University of Michigan
Comprehensive Cancer Center

Maciej Mrugala, MD, PhD, MPH Ψ
Fred Hutchinson Cancer Research
Center/University of Washington

Jana Portnow, MD † Ψ
City of Hope
Comprehensive Cancer Center

Principles of Radiation Therapy

Dennis C. Shrieve, MD, PhD/Lead §
Huntsman Cancer Institute
at the University of Utah

Steven S. Brem, MD/¶
H. Lee Moffitt Cancer Center
and Research Institute

Larry Junck, MD Ψ
University of Michigan
Comprehensive Cancer Center

Jay J. Loeffler, MD §
Dana-Farber/Brigham and Women's
Cancer Center | Massachusetts General
Hospital Cancer Center

Moshe H. Maor, MD §
The University of Texas
M.D. Anderson Cancer Center

Allen K. Sills, Jr., MD ¶
St. Jude Children's Research
Hospital/University of Tennessee
Cancer Institute

Continue

† Medical oncology
‡ Hematology/Hematology oncology
§ Radiotherapy/Radiation oncology
Ψ Neurology/neuro-oncology
¶ Surgery/Surgical oncology

Table of Contents

- [NCCN Central Nervous System Cancers Panel Members](#)
- [NCCN Central Nervous System Cancers Sub-Committee Members](#)
- [Summary of Guidelines Updates](#)
- [Adult Low-Grade Infiltrative Supratentorial Astrocytoma/
Oligodendroglioma \(excluding pilocytic astrocytoma\) \(ASTR-1\)](#)
- [Adult Intracranial Ependymoma \(EPEN-1\)](#)
- [Anaplastic Astrocytoma/Anaplastic Oligodendroglioma/
Glioblastoma Multiforme \(GLIO-1\)](#)
- [Limited \(1-3\) Metastatic Lesions \(LTD-1\)](#)
- [Multiple \(>3\) Metastatic Lesions \(MU-1\)](#)
- [Carcinomatous/Lymphomatous Meningitis \(CLMEN-1\)](#)
- [Nonimmunosuppressed Primary CNS Lymphoma \(PCNS-1\)](#)
- [Metastatic Spine Tumors \(SPINE-1\)](#)
- Principles of Brain Tumor Therapy:
 - [Imaging \(BRAIN-A\)](#)
 - [Surgery \(BRAIN-B\)](#)
 - [Radiation \(BRAIN-C\)](#)
 - [Systemic Therapy \(BRAIN-D\)](#)

[Guidelines Index](#)

[Print the Central Nervous System Cancers Guideline](#)

These guidelines are a statement of evidence and consensus of the authors regarding their views of currently accepted approaches to treatment. Any clinician seeking to apply or consult these guidelines is expected to use independent medical judgment in the context of individual clinical circumstances to determine any patient's care or treatment. The National Comprehensive Cancer Network makes no representations or warranties of any kind, regarding their content use or application and disclaims any responsibility for their application or use in any way. These guidelines are copyrighted by National Comprehensive Cancer Network. All rights reserved. These guidelines and the illustrations herein may not be reproduced in any form without the express written permission of NCCN. ©2009.

[For help using these documents, please click here](#)

[Discussion](#)

[References](#)

This manuscript is being updated to correspond with the newly updated algorithm.

Clinical Trials: The NCCN believes that the best management for any cancer patient is in a clinical trial. Participation in clinical trials is especially encouraged.

To find clinical trials online at NCCN member institutions, [click here:](#)
nccn.org/clinical_trials/physician.html

NCCN Categories of Evidence and Consensus: All recommendations are Category 2A unless otherwise specified.

See [NCCN Categories of Evidence and Consensus](#)

Summary of the Guidelines updates

Summary of major changes in the 1.2009 version of the Central Nervous System Cancers guidelines from the 1.2008 version include:

Adult Low Grade Infiltrative Supratentorial Astrocytoma/Oligodendroglioma (excluding pilocytic astrocytoma)

(ASTR-1)

• Surgery; Top branch:

- ▶ “Maximal excision” changed to “Maximal safe resection”. (Change made throughout the Central Nervous System Cancers guidelines.)
- ▶ “Age > 45 y” changed to “Age > 40 y” and “Age ≤ 45 y” changed to “Age ≤ 40 y”.

(ASTR-2)

- Prior fractionated external beam RT branch; Far right: “Reirradiation, especially if progression free survival...” changed to “Reirradiation with conformal RT, especially...”
- No prior fractionated external beam RT branch; Far right: “RT or chemotherapy...” changed to “Fractionated external beam RT or chemotherapy...”
- Footnote “k” regarding the propensity of astrocytomas and oligodendrogliomas to undergo malignant transformation is new to the page.

Adult Intracranial Ependymoma (excluding subependymoma and myxopapillary)

(EPEN-2)

• Pathology; Top branch:

- ▶ Second column: “...and spine MRI; ± CSF analysis” changed to “...and spine MRI; Consider CSF analysis”.
- ▶ Postoperative Staging: The phrase “if done” was removed after “CSF negative”.
- ▶ Footnote “f” stating “If MRI spine negative, then CSF analysis should be done” is new to the page.

(EPEN-3)

- After “Spine or brain recurrence”: The panel added a new column, “Clinical staging”, with the recommendation “Complete neuroaxis imaging by MRI and CSF analysis.”

Anaplastic Astrocytoma/Anaplastic Oligodendroglioma/Glioblastoma Multiforme (including mixed anaplastic oligoastrocytoma)

(GLIO-1)

- Clinical Impression: “Maximal resection feasible” changed to “Maximal safe resection feasible with goal for image-verified complete resection.”
- Surgery; Bottom branch: Changed to “...or Subtotal resection (MRI after resection)”.

(GLIO-2)

- Pathology: “Consider 1p19q analysis (category 1 for prognostic marker)” was added.
- Anaplastic astrocytoma, anaplastic oligodendroglioma; Adjuvant treatment: “Fractionated external beam RT ± chemotherapy (category 2B or AA and category 1 for AO)” and the following recommendation to “Observe or Post RT chemotherapy” changed to “Fractionated external beam RT or Chemotherapy or Combined chemoradiation (category 3)”.
- Glioblastoma multiforme pathway was revised.
- Follow-up: “MRI...then every 2-3 mo for 2-3 y” changed to “MRI...then every 2-4 mo for 2-3 y, then less frequently”.

(GLIO-3)

- Unresectable pathway: “Consider reirradiation” changed from category 2A to category 2B. “Best supportive care if poor performance status” was added.
- Footnote “m” regarding distinguishing between diagnosis of recurrence and pseudoprogression on neuroimaging is new to the page.

Note: All recommendations are category 2A unless otherwise indicated.

Clinical Trials: NCCN believes that the best management of any cancer patient is in a clinical trial. Participation in clinical trials is especially encouraged.

[Continued on next page](#)

UPDATES
1 of 3

Summary of the Guidelines updates

Limited (1-3) Metastatic Lesions

(LTD-1)

- “No known history of cancer”: New pathway for “Suspected tumor found outside CNS” was added.

(LTD-2)

- Disseminated systemic disease; Primary treatment: After “WBRT” the panel added “Consider chemotherapy (category 2B)”.
- Resectable; Primary Treatment: Recommendation changed to “Surgical resection, followed by WBRT ± stereotactic radiosurgery”. “...category 2A for 2-3 metastases” changed to “category 2B”.
- Footnote “g” regarding considering chemotherapy in select patients is new to the page.

(LTD-3)

- Treatment: “Stereotactic radiosurgery” changed to “Single dose or fractionated stereotactic RT”.

(LTD-4)

- No prior WBRT: The panel added “Best supportive care”.

Multiple (>3) Metastatic Lesions

(MU-1)

- Primary treatment: After WBRT, the panel removed “± stereotactic radiosurgery”.

Carcinomatous/Lymphomatous Meningitis

(CLMEN-1)

- Workup: The panel removed the phrase “if safe” after “CSF exam”.
- Diagnosis: “Positive CSF cytology” changed to “CSF positive for tumor cells”.
- Footnotes “b”, “c”, “d” are new to the page.
- Footnote “e” was revised.

(CLMEN-2)

- After “Strongly consider CSF flow scan”, the panel added “Consider placing ventricular catheter and subcutaneous reservoir”.
- Good risk; Treatment: The recommendation changed to “Involved field RT to bulky disease, symptomatic sites, or sites of CSF flow disruption, then intra-CSF chemotherapy”.
- “Intrathecal chemotherapy” changed to “Intra-CSF chemotherapy” throughout the CNS guidelines.

(CLMEN-3)

- Normal flow; Primary Treatment: “...reassess from lumbar region” changed to “...reassess from a different site”.

(CLMEN-4)

- “CSF cytology positive”
 - Top branch: “Consider switching intra-CSF drugs for 4 wks” changed to “Consider switching intra-CSF drugs and treat for 4 wks before re-testing CSF”.
 - Bottom branch: The recommendation “Consider switching intra-CSF drug” was added.

Note: All recommendations are category 2A unless otherwise indicated.

Clinical Trials: NCCN believes that the best management of any cancer patient is in a clinical trial. Participation in clinical trials is especially encouraged.

[Continued on next page](#)

Summary of the Guidelines updates

Primary CNS Lymphoma (Nonimmunosuppressed)

(PCNS-1)

- Diagnosis by tissue evaluation: “CT/MRI suggestive of...” changed to “MRI suggestive of...” with corresponding footnote “b” that states “Contrast CT, if patient cannot have MRI”.
- Third column: Recommendations regarding CSF sampling, eye exam, and brain biopsy were revised.

(PCNS-2)

- Workup; Third bullet: “MRI” changed to “Spine MRI, if symptomatic or positive CSF”.
- Footnote “d” regarding lumbar puncture cautions is new to the page.

(PCNS-3)

- Treatment: The panel added “Consider high-dose therapy with stem cell rescue (category 2B)” to all three pathways.

(BRAIN-A)---Principles of Brain Tumor Imaging

- Fourth bullet; MR Perfusion; Limitations: The panel added “small volume lesions or tumors in the spinal cord.”
- Fifth bullet: After Body PET, the panel removed “SPECT”.

(BRAIN-C)---Principles of Brain Tumor Radiation Therapy

- Low Grade Gliomas: The panel added, “SRS has not been established to have a role in the management of low grade gliomas. Although it is used selectively in patients who have not had radiotherapy.”
- Primary CNS Lymphoma: The panel added, “Lower doses of radiation are less toxic and may be as effective.”

(BRAIN-D)---Principles of Brain Tumor Systemic Therapy (1 of 3)

- Adult Low-Grade Infiltrative Supratentorial Astrocytoma/Oligodendroglioma; Adjuvant Treatment: “Temozolomide 5 day high dose 5/28 schedule” changed to “Temozolomide 150-200 mg/m² 5/28 schedule”.
- Glioblastoma Multiforme; Recurrence/Salvage therapy: “Bevacizumab with irinotecan” changed to “Bevacizumab ± irinotecan”.
- Anaplastic Astrocytoma/Anaplastic Oligodendroglioma:
 - ▶ The panel added “Combined Chemoradiation (category 3)” with the following regimen “Concurrent temozolomide 75 mg/m² daily”.
 - ▶ Recurrence/Salvage therapy: “Bevacizumab with irinotecan” changed to “Bevacizumab ± irinotecan”.
- Footnote “α” that states, “Platinum-based regimens include cisplatin or carboplatin” is new to the page.

(BRAIN-D)---Principles of Brain Tumor Systemic Therapy (2 of 3)

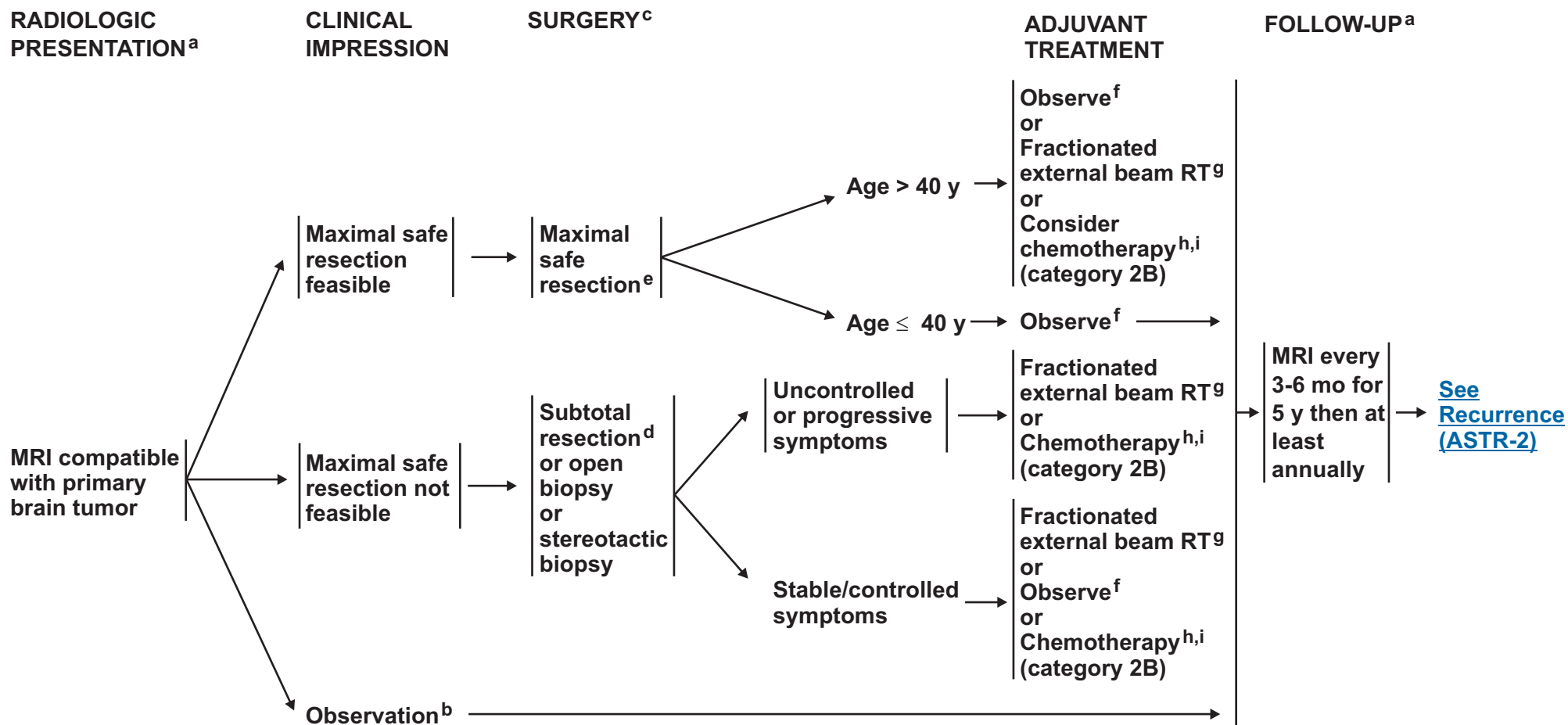
- Limited Metastatic or Multiple Metastatic Lesions; Recurrent Disease:
 - ▶ Third arrow: The panel added “cyclophosphamide”.
 - ▶ Fourth arrow: The panel added “Cisplatin, etoposide (breast)”.
- Primary CNS Lymphoma; Recurrence or Progressive Disease:
 - ▶ “Consider HDT with stem cell rescue” was added.
 - ▶ “Platinum, high-dose cytarabine, dexamethasone” was removed.

Note: All recommendations are category 2A unless otherwise indicated.

Clinical Trials: NCCN believes that the best management of any cancer patient is in a clinical trial. Participation in clinical trials is especially encouraged.

[Continued on next page](#)

(Excluding Pilocytic Astrocytoma)



^aSee Principles of Brain Tumor Imaging (BRAIN-A).

^bSurgery is generally recommended, but serial observations are appropriate for selected patients.

^cSee Principles of Brain Tumor Surgery (BRAIN-B).

^dConsider testing for deletions in 1p19q if tumor has components of oligodendroglioma for prognostic purposes.

^ePost-operative MRI should be done within 72 hours after surgery.

^fRegular follow-up is essential for patients receiving observation alone after resection.

^gSee Principles of Brain Tumor Radiation Therapy (BRAIN-C).

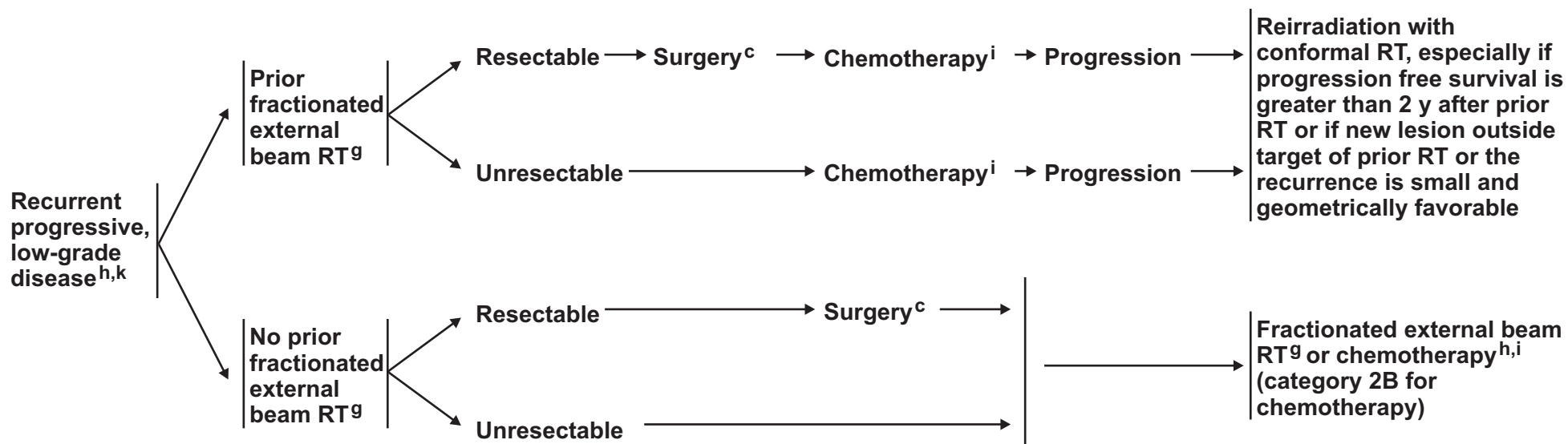
^hOligodendrogliomas, particularly those that have chromosomal loss of combined 1p19q, have been reported to be sensitive to alkylator chemotherapy. Consider chemotherapy for these patients.

ⁱSee Principles of Brain Tumor Systemic Therapy (BRAIN-D).

Note: All recommendations are category 2A unless otherwise indicated.

Clinical Trials: NCCN believes that the best management of any cancer patient is in a clinical trial. Participation in clinical trials is especially encouraged.

RECURRENCE^j



^cSee Principles of Brain Tumor Surgery (BRAIN-B).

^gSee Principles of Brain Tumor Radiation Therapy (BRAIN-C).

^hOligodendrogliomas, particularly those that have chromosomal loss of combined 1p19q, have been reported to be sensitive to alkylator chemotherapy. Consider chemotherapy for these patients.

ⁱSee Principles of Brain Tumor Systemic Therapy (BRAIN-D).

^jRecurrence on neuroimaging can be confounded by treatment effects. Strongly consider tumor tissue sampling if there is a high index of suspicion of recurrence.

^kAt recurrence, there is a high propensity for these tumors to undergo malignant transformation. Sixty percent or more of astrocytomas will dedifferentiate and 40%-50% of oligodendrogliomas will undergo transformation.

Note: All recommendations are category 2A unless otherwise indicated.

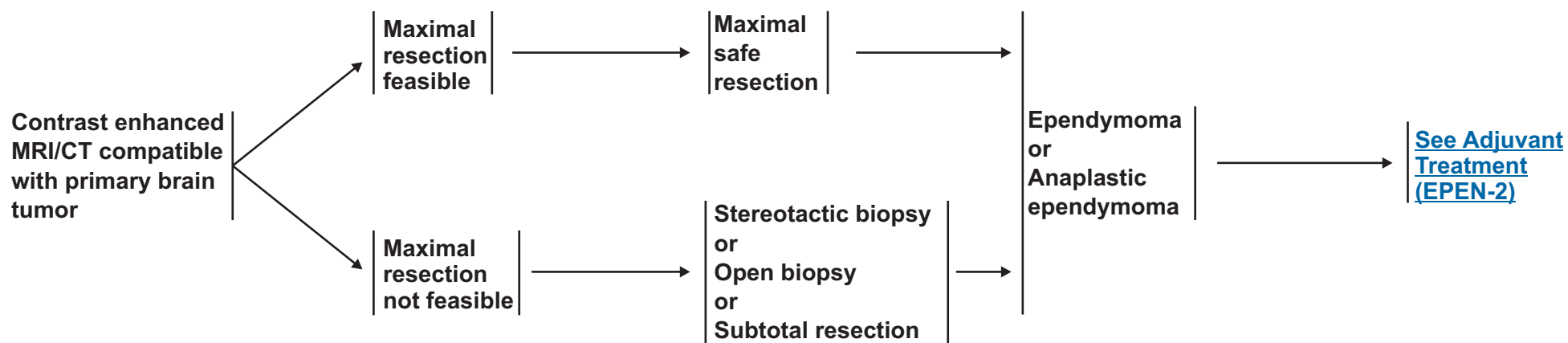
Clinical Trials: NCCN believes that the best management of any cancer patient is in a clinical trial. Participation in clinical trials is especially encouraged.

**RADIOLOGIC
PRESENTATION^a**

**CLINICAL
IMPRESSION**

SURGERY^b

PATHOLOGY



^aSee Principles of Brain Tumor Imaging (BRAIN-A).

^bSee Principles of Brain Tumor Surgery (BRAIN-B).

Note: All recommendations are category 2A unless otherwise indicated.
Clinical Trials: NCCN believes that the best management of any cancer patient is in a clinical trial. Participation in clinical trials is especially encouraged.

PATHOLOGY

POSTOPERATIVE STAGING

ADJUVANT TREATMENT^g

Ependymoma, status post maximal safe resection

Contrast enhanced brain^c and spine MRI;^d Consider CSF analysis^{e,f}

Total resection, MRI spine negative, CSF negative

Consider limited-field fractionated external beam RT^g or Observe

Subtotal resection, MRI spine negative, CSF negative

Limited-field fractionated external beam RT^g

Total or subtotal resection, MRI spine positive or CSF positive

Craniospinal RT^g

Anaplastic ependymoma, status post maximal resection

Contrast enhanced brain^c and spine MRI;^d CSF^e analysis

Total or subtotal resection, MRI spine negative, CSF negative

Limited-field fractionated external beam RT^g

Total or subtotal resection, MRI spine positive or CSF positive

Craniospinal RT^g

Ependymoma or Anaplastic ependymoma status post stereotactic or open biopsy or subtotal resection

Contrast enhanced brain^c and spine MRI;^d CSF^e analysis

MRI spine negative, CSF negative

Limited-field fractionated external beam RT^g

MRI spine positive or CSF positive

Craniospinal RT^g

[See Follow-up and Recurrence \(EPEN-3\)](#)

^cWithin 24-72 hours.

^dSpine MRI should be delayed by at least 2-3 weeks post surgery to avoid post surgical artifacts.

^eLumbar puncture for CSF should be delayed at least 2 weeks after surgery to avoid possible false positive cytology. May be contraindicated (eg, posterior fossa mass).

^fIf MRI spine negative, then CSF analysis should be done.

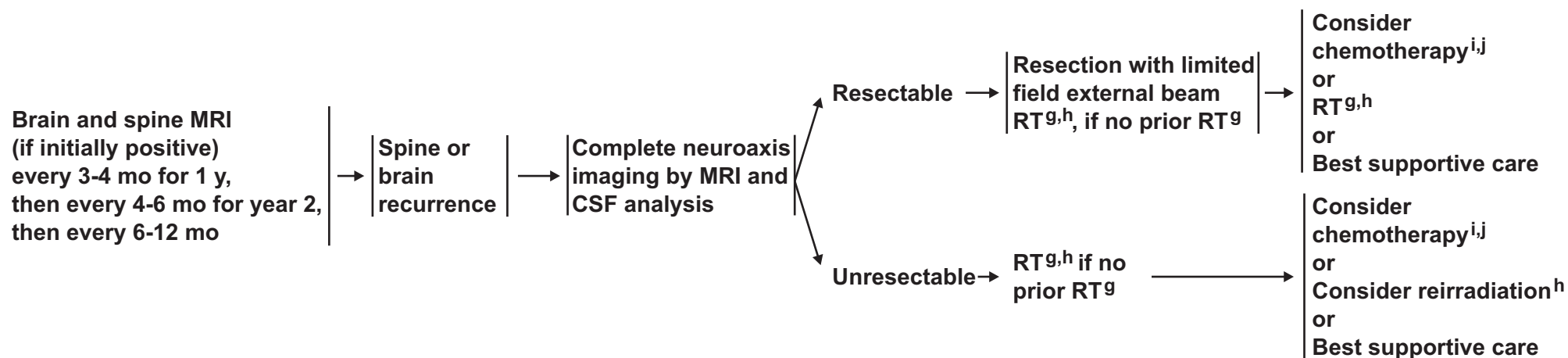
^g[See Principles of Brain Tumor Radiation Therapy \(BRAIN-C\).](#)

Note: All recommendations are category 2A unless otherwise indicated.
Clinical Trials: NCCN believes that the best management of any cancer patient is in a clinical trial. Participation in clinical trials is especially encouraged.

FOLLOW-UP^a

RECURRENCE

CLINICAL STAGING



^aSee Principles of Brain Tumor Imaging (BRAIN-A).

^gSee Principles of Brain Tumor Radiation Therapy (BRAIN-C).

^hConsider stereotactic radiosurgery (SRS) if geometrically favorable.

ⁱThere are case series reports indicating responses to chemotherapy.

^jSee Principles of Brain Tumor Systemic Therapy (BRAIN-D).

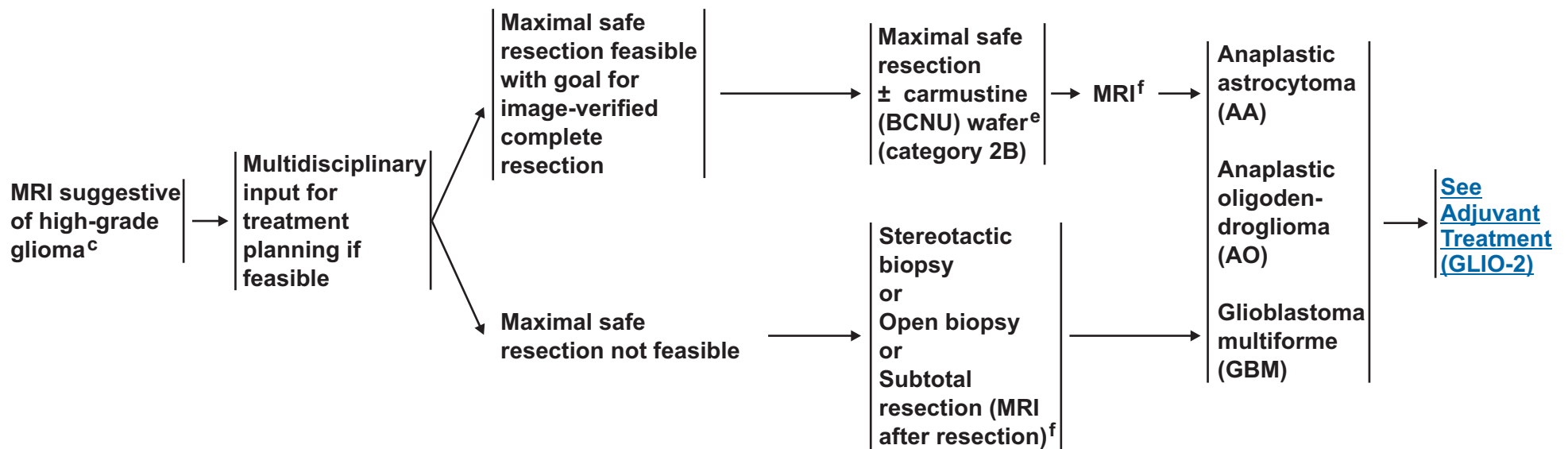
Note: All recommendations are category 2A unless otherwise indicated.
Clinical Trials: NCCN believes that the best management of any cancer patient is in a clinical trial. Participation in clinical trials is especially encouraged.

RADIOLOGIC
PRESENTATION^b

CLINICAL
IMPRESSION

SURGERY^d

PATHOLOGY



^aThis pathway also includes the classification of mixed anaplastic oligoastrocytoma.

^b[See Principles of Brain Tumor Imaging \(BRAIN-A\).](#)

^cBiopsy first if MRI compatible with CNS lymphoma.

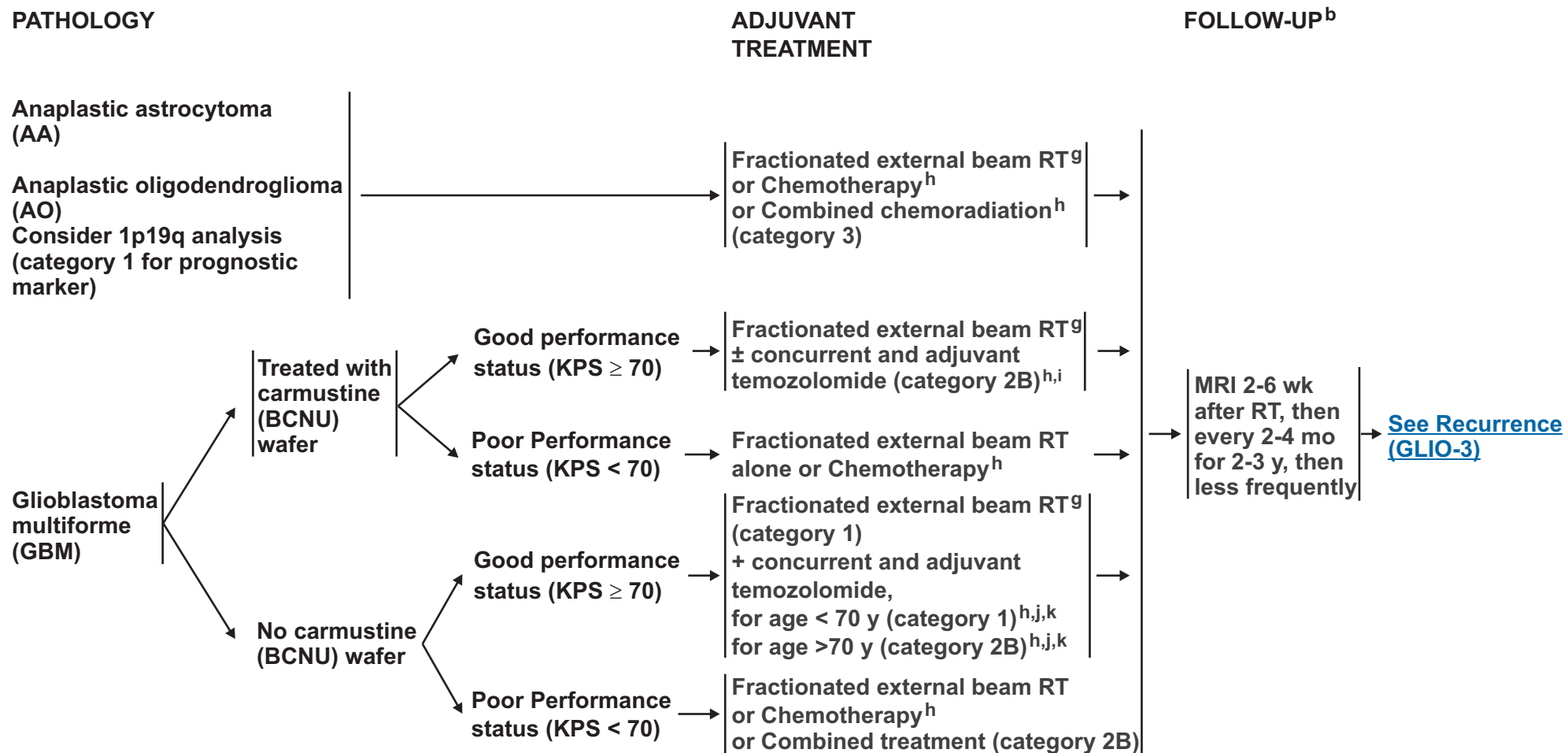
^d[See Principles of Brain Tumor Surgery \(BRAIN-B\).](#)

^eIf frozen section diagnosis supports high-grade glioma.

^fPost-operative MRI should be done within 72 hours after surgery.

Note: All recommendations are category 2A unless otherwise indicated.

Clinical Trials: NCCN believes that the best management of any cancer patient is in a clinical trial. Participation in clinical trials is especially encouraged.



^aThis pathway also includes the classification of mixed anaplastic oligoastrocytoma.

^bSee Principles of Brain Tumor Imaging (BRAIN-A).

^gSee Principles of Brain Tumor Radiation Therapy (BRAIN-C).

^hSee Principles of Brain Tumor Systemic Therapy (BRAIN-D).

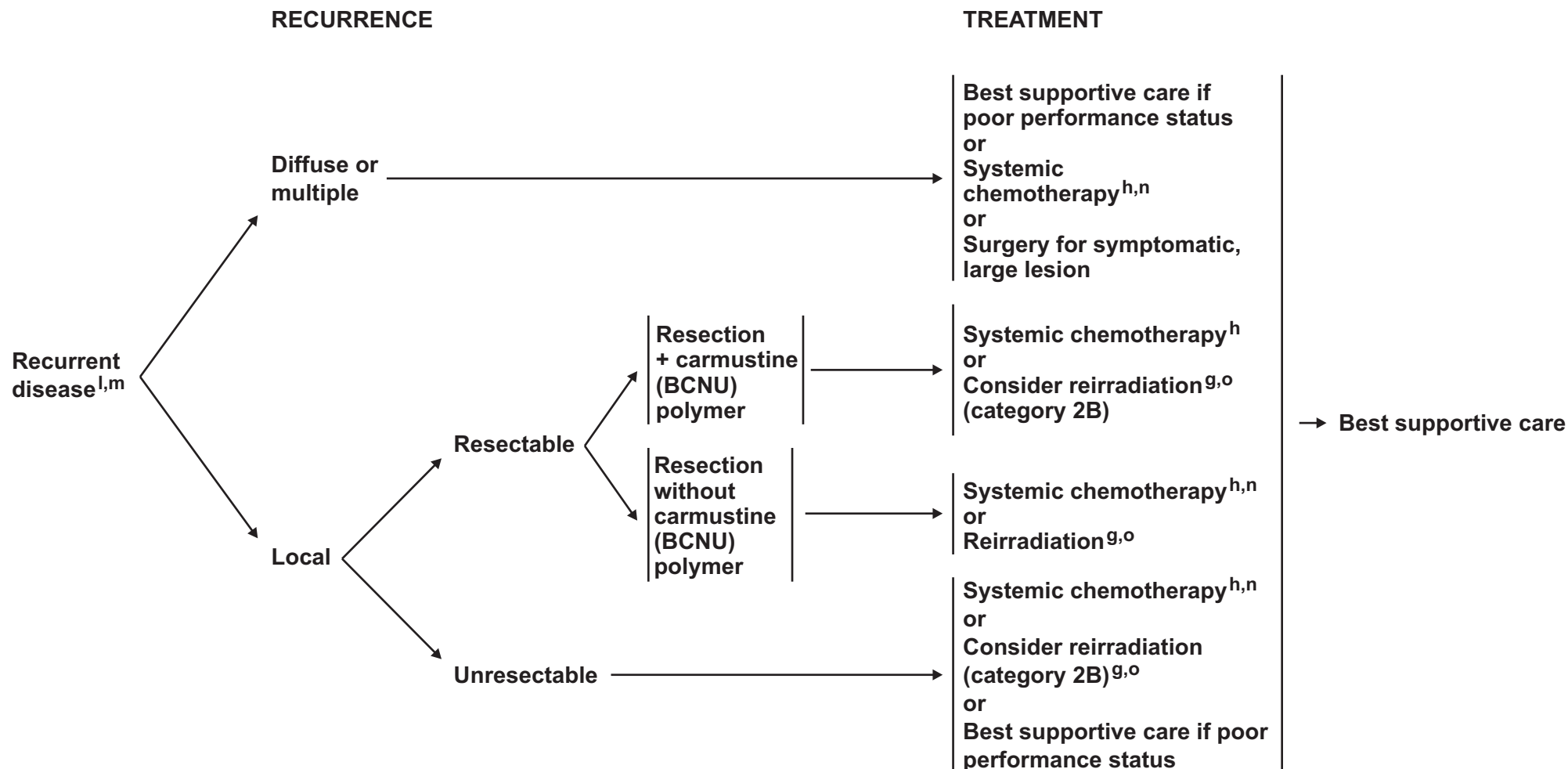
ⁱCombination of agents may lead to increased toxicity or radiographic changes.

^jStupp R, Mason WP, van den Bent MJ et al. Radiotherapy plus concomitant and adjuvant temozolomide for glioblastoma. N Engl J Med 2005;352:987-996.

^kDuration of treatment for glioblastomas beyond 6 months is unknown. Duration of therapy for anaplastic astrocytoma is unknown.

Note: All recommendations are category 2A unless otherwise indicated.

Clinical Trials: NCCN believes that the best management of any cancer patient is in a clinical trial. Participation in clinical trials is especially encouraged.



^aThis pathway also includes the classification of mixed anaplastic oligoastrocytoma.

^gSee Principles of Brain Tumor Radiation Therapy (BRAIN-C).

^hSee Principles of Brain Tumor Systemic Therapy (BRAIN-D).

^lConsider MR spectroscopy, MR perfusion, or body PET to rule out radiation necrosis.

^mWithin the first 3 months after completion of RT and concomitant temozolomide, diagnosis of recurrence can be indistinguishable from pseudoprogression on neuroimaging. With pseudoprogression, stabilization or improvement should be expected within 3 mo of the end of radiotherapy.

ⁿAnaplastic oligodendrogliomas have been reported to be especially sensitive to chemotherapy. Chemotherapy using temozolomide or nitrosourea-based regimens may be appropriate.

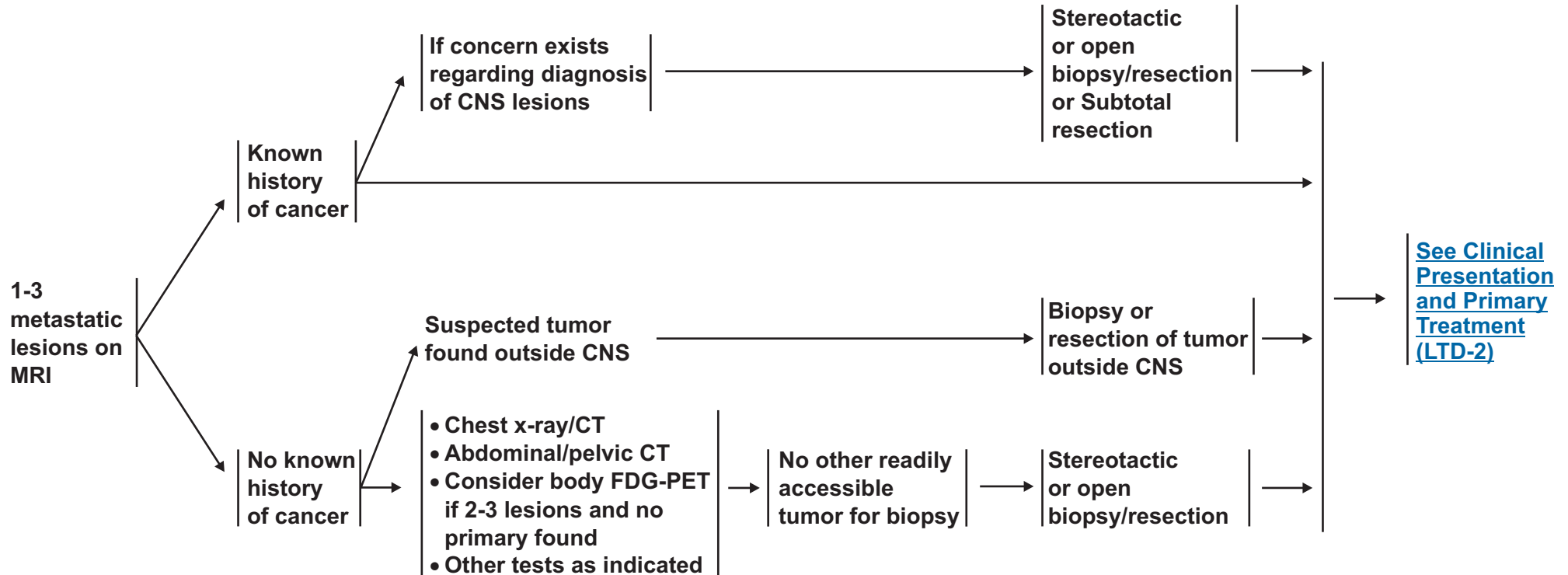
^oEspecially if long interval since prior RT and/or good response to prior RT.

Note: All recommendations are category 2A unless otherwise indicated.

Clinical Trials: NCCN believes that the best management of any cancer patient is in a clinical trial. Participation in clinical trials is especially encouraged.

CLINICAL
PRESENTATION^a

WORKUP



^aSee Principles of Brain Tumor Imaging (BRAIN-A).

Note: All recommendations are category 2A unless otherwise indicated.
Clinical Trials: NCCN believes that the best management of any cancer patient is in a clinical trial. Participation in clinical trials is especially encouraged.

CLINICAL
PRESENTATION

Disseminated
systemic disease
with poor systemic
treatment options^{b,c}

Stable systemic
disease or
Reasonable systemic
treatment options^c

Resectable^d

Unresectable

PRIMARY TREATMENT^{e,f}

WBRT^f
Consider chemotherapy^g
(category 2B)

Surgical resection, followed by WBRT^f
± stereotactic radiosurgery (category
1 for 1 metastasis, and
category 2B for 2-3 metastases)
or
Stereotactic radiosurgery (SRS)^f
+ WBRT (category 1 for 1 metastasis,
category 2A for 2-3 metastases)
or
Stereotactic radiosurgery^f alone
(category 2B)

WBRT^f and/or
radiosurgery

[See Follow-up
and
Recurrence
\(LTD-3\)](#)

^bConsider surgery to relieve mass effect.

^cSolid brain metastases with systemic non-primary CNS lymphoma are not well defined, but treatment may include systemic treatment, whole-brain radiotherapy, or focal RT.

^dChoice of therapy depends in part on size of lesion, eg, small (< 2cm), deep, non-symptomatic lesions may consider treatment with SRS versus larger, symptomatic lesions that may be more appropriate for surgery. Decisions also depend on institutional practice.

^e[See Principles of Brain Tumor Surgery \(BRAIN-B\).](#)

^f[See Principles of Brain Tumor Radiation Therapy \(BRAIN-C\).](#)

^gChemotherapy may be considered in select patients (eg, patients who have asymptomatic brain metastases that are otherwise small and who have not had prior chemotherapy). Treatment as per the regimens of the primary tumor.

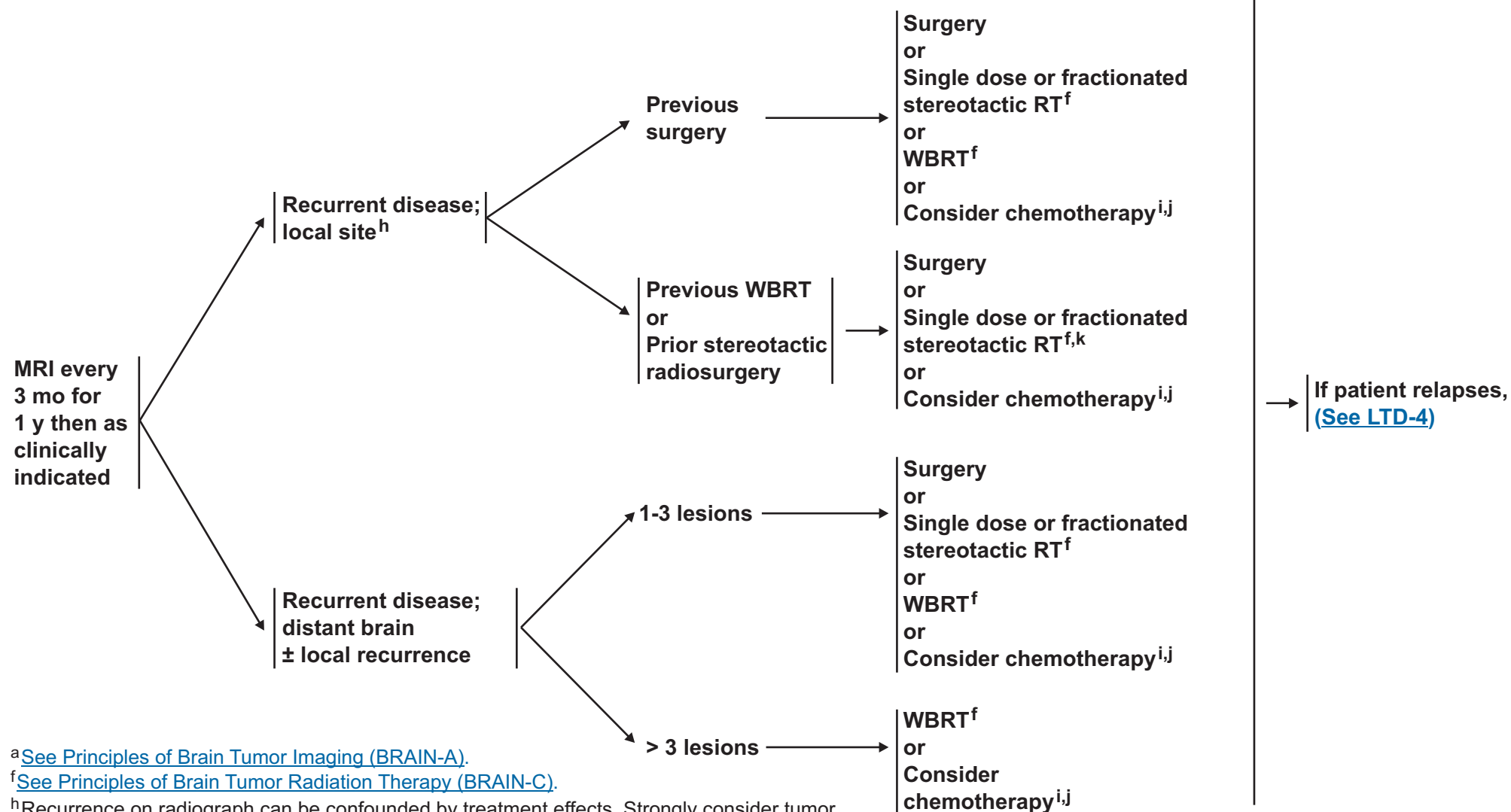
Note: All recommendations are category 2A unless otherwise indicated.

Clinical Trials: NCCN believes that the best management of any cancer patient is in a clinical trial. Participation in clinical trials is especially encouraged.

FOLLOW-UP^a

RECURRENCE

TREATMENT



^aSee Principles of Brain Tumor Imaging (BRAIN-A).

^fSee Principles of Brain Tumor Radiation Therapy (BRAIN-C).

^hRecurrence on radiograph can be confounded by treatment effects. Strongly consider tumor tissue sampling if there is a high index of suspicion of recurrence.

ⁱSee Principles of Brain Tumor Systemic Therapy (BRAIN-D).

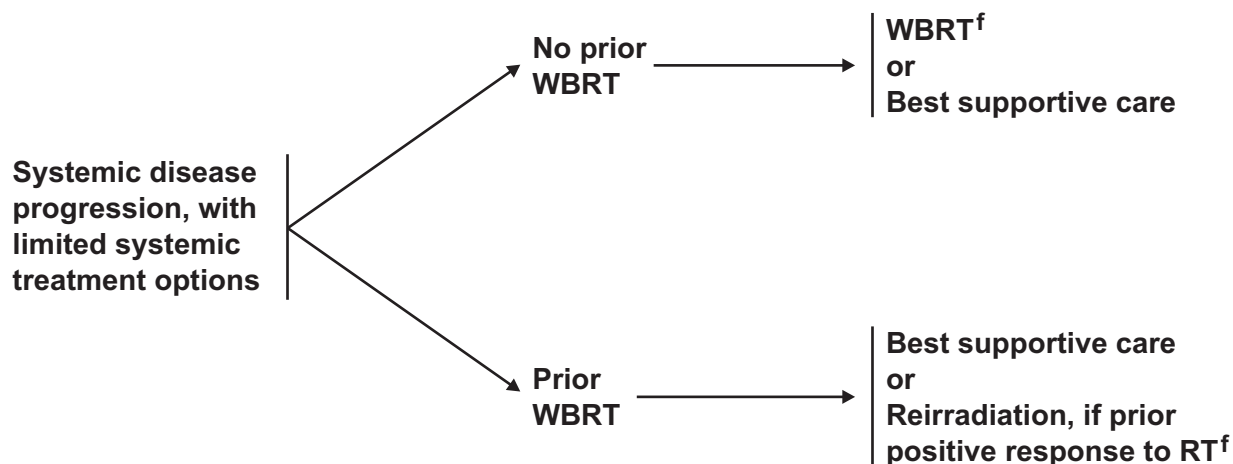
^jLocal or systemic chemotherapy.

^kIf patient had previous SRS with a good response > 6 mo, then reconsider SRS if imaging supports active tumor and not necrosis.

Note: All recommendations are category 2A unless otherwise indicated.
Clinical Trials: NCCN believes that the best management of any cancer patient is in a clinical trial. Participation in clinical trials is especially encouraged.

RECURRENCE

TREATMENT



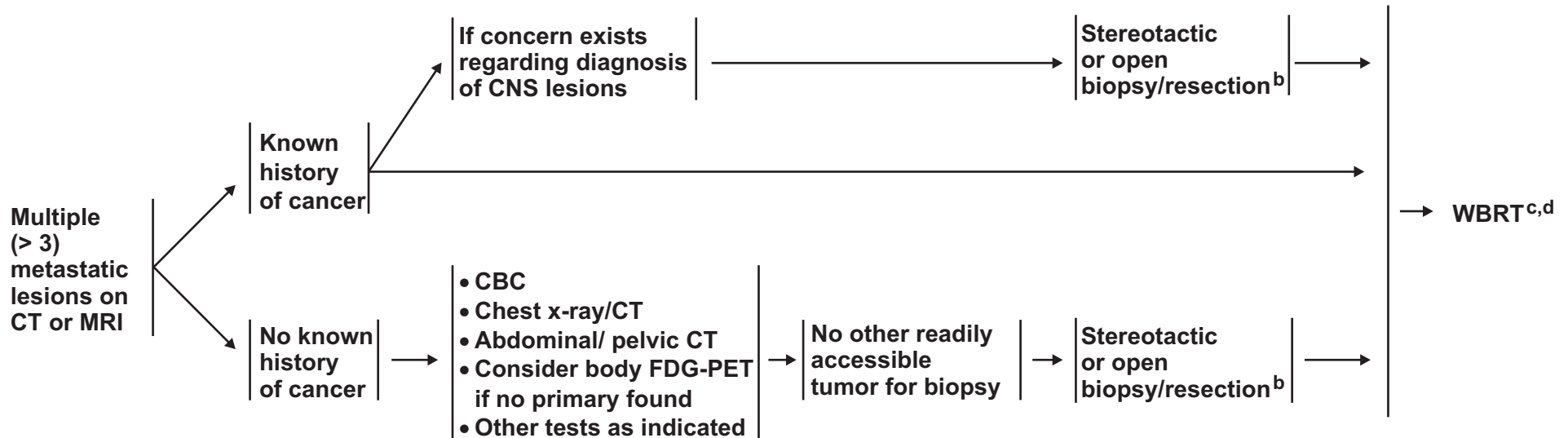
^fSee Principles of Brain Tumor Radiation Therapy (BRAIN-C).

Note: All recommendations are category 2A unless otherwise indicated.
Clinical Trials: NCCN believes that the best management of any cancer patient is in a clinical trial. Participation in clinical trials is especially encouraged.

CLINICAL
PRESENTATION^a

WORKUP

PRIMARY
TREATMENT^c



[See Follow-up and Recurrence \(MU-2\)](#)

^aSee Principles of Brain Tumor Imaging (BRAIN-A).

^bConsider surgery to relieve mass effect.

^cSee Principles of Brain Tumor Radiation Therapy (BRAIN-C).

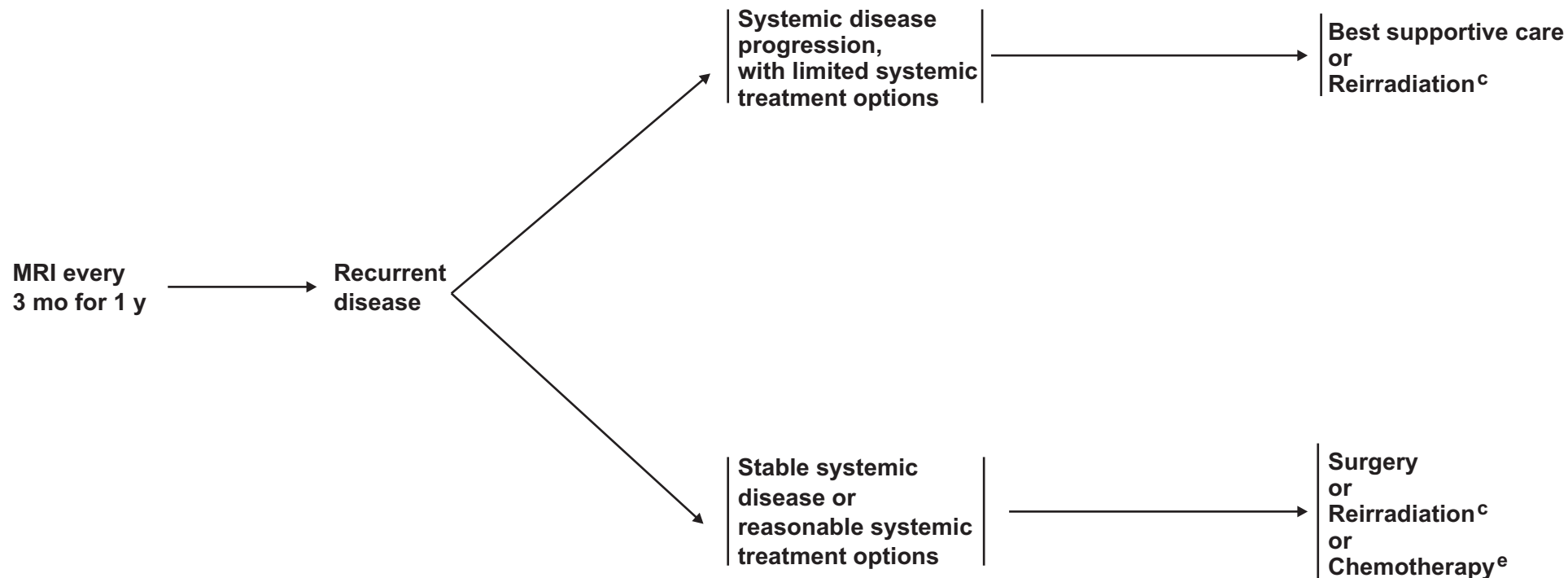
^dSRS should only be considered in selected cases (eg, limited number of lesions).

Note: All recommendations are category 2A unless otherwise indicated.
Clinical Trials: NCCN believes that the best management of any cancer patient is in a clinical trial. Participation in clinical trials is especially encouraged.

FOLLOW-UP^a

RECURRENCE

TREATMENT

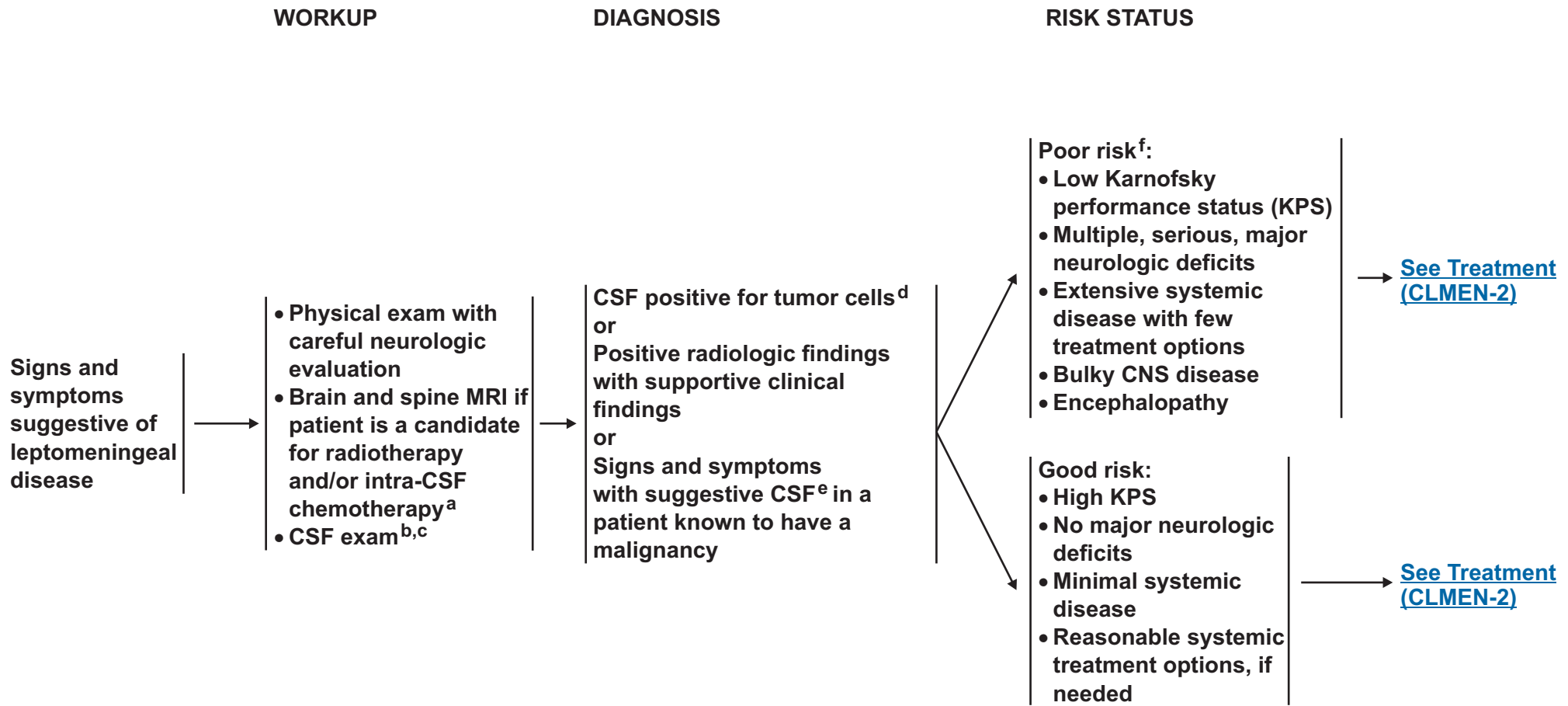


^aSee Principles of Brain Tumor Imaging (BRAIN-A).

^cSee Principles of Brain Tumor Radiation Therapy (BRAIN-C).

^eSee Principles of Brain Tumor Systemic Therapy (BRAIN-D).

Note: All recommendations are category 2A unless otherwise indicated.
Clinical Trials: NCCN believes that the best management of any cancer patient is in a clinical trial. Participation in clinical trials is especially encouraged.



^aIntra-CSF chemotherapy includes intrathecal (intralumbar) and intraventricular (intra-Ommaya).

^bCaution is indicated in patients who are anticoagulated, thrombocytopenic, or who have a bulky intra-cranial mass.

^cWith all malignancies, send for a cell count, differential (including hematopathology review), glucose, and protein. With lymphoma, add flow cytometry. With malignancies other than lymphoma, add cytopathology.

^dFor most malignancies, CSF is positive when cytopathology is positive. For lymphoma, generally CSF is positive when hemapathology or flow cytometry are positive.

^eSuggestive CSF includes high WBC, low glucose, and high protein. If CSF is not positive for tumor cells, a second lumbar puncture is sometimes helpful.

^fPatients with exceptionally chemosensitive tumors (eg, small cell lung cancer, lymphoma) may be treated.

Note: All recommendations are category 2A unless otherwise indicated.

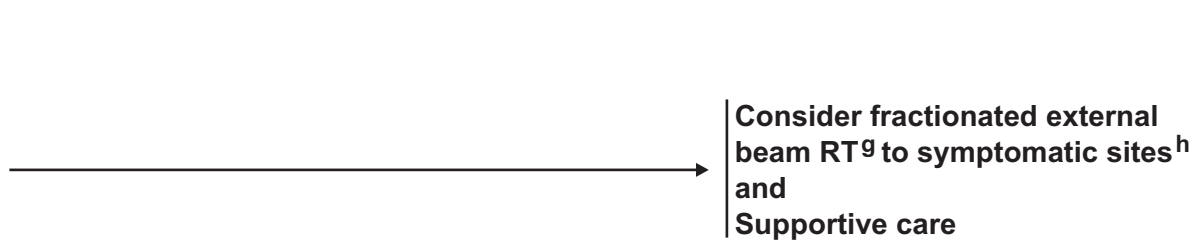
Clinical Trials: NCCN believes that the best management of any cancer patient is in a clinical trial. Participation in clinical trials is especially encouraged.

RISK STATUS

TREATMENT

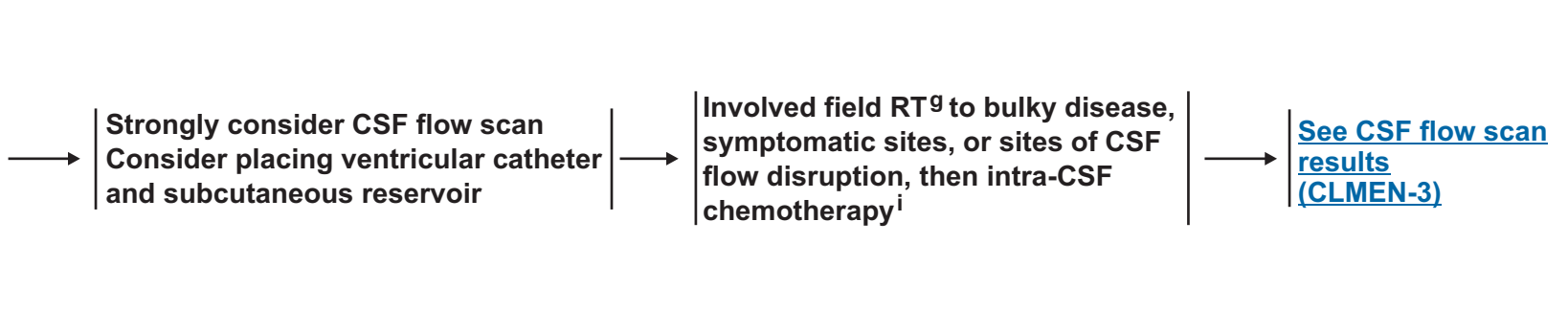
Poor risk^f:

- Low KPS
- Multiple, serious, major neurologic deficits
- Extensive systemic disease with few treatment options
- Bulky CNS disease
- Encephalopathy



Good risk:

- High KPS
- No major neurologic deficits
- Minimal systemic disease
- Reasonable systemic treatment options, if needed



^fPatients with exceptionally chemosensitive tumors (eg, SCLC, lymphoma) may be treated.

^g[See Principles of Brain Tumor Radiation Therapy \(BRAIN-C\).](#)

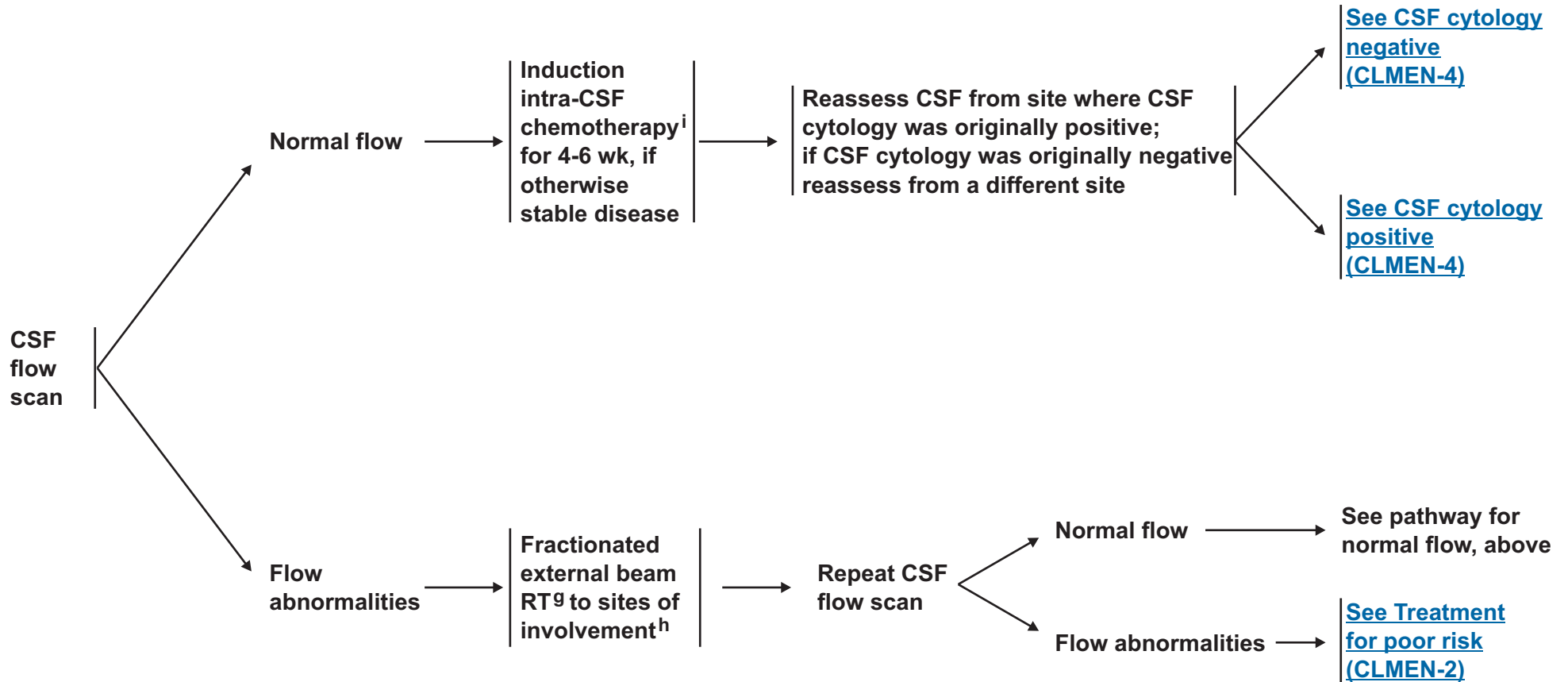
^hUsually WBRT and/or partial spine field recommended.

ⁱ[See Principles of Brain Tumor Systemic Therapy \(BRAIN-D\).](#)

Note: All recommendations are category 2A unless otherwise indicated.

Clinical Trials: NCCN believes that the best management of any cancer patient is in a clinical trial. Participation in clinical trials is especially encouraged.

PRIMARY TREATMENT



^gSee Principles of Brain Tumor Radiation Therapy (BRAIN-C).

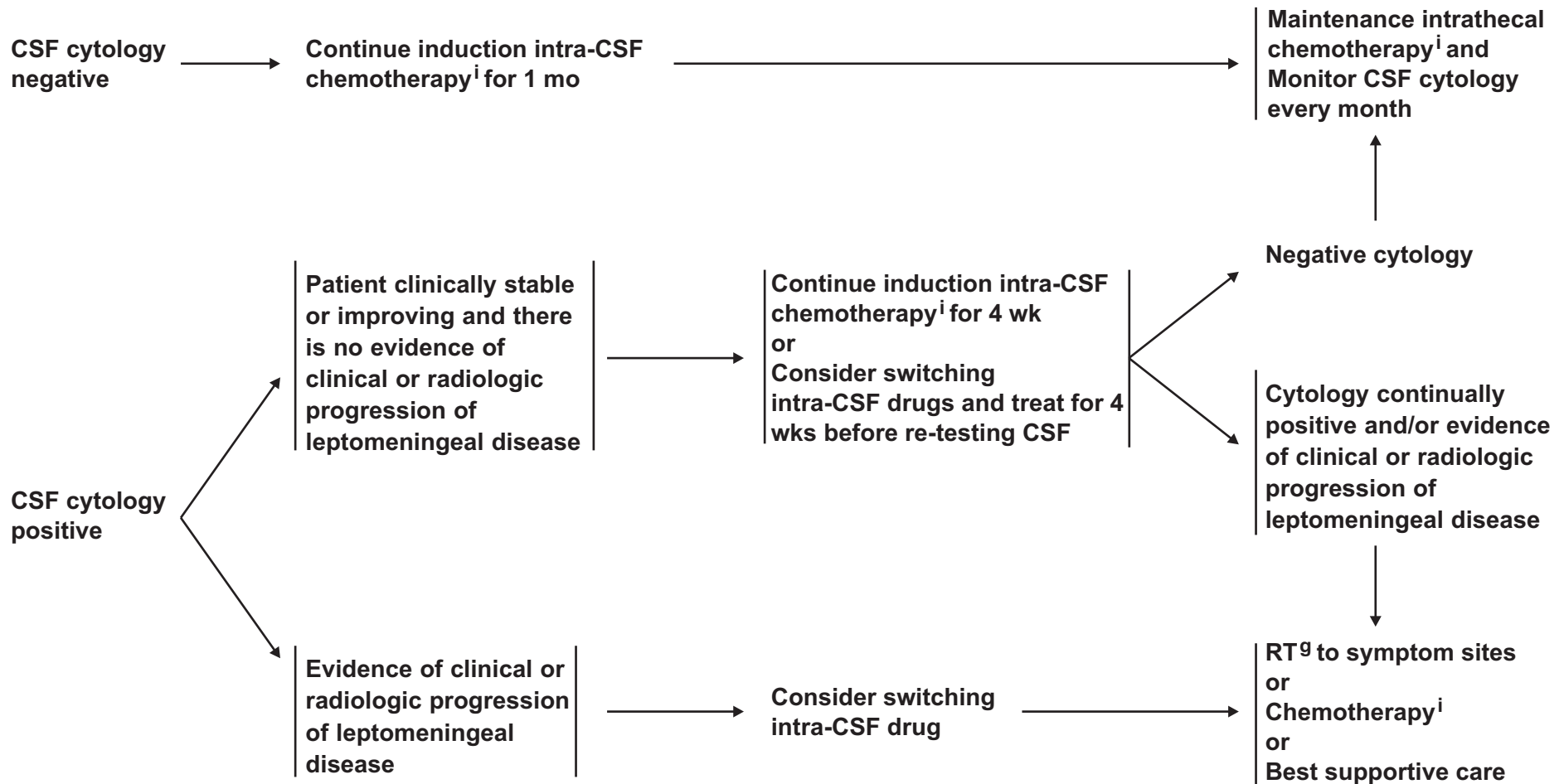
^hUsually WBRT and/or partial spine field recommended.

ⁱSee Principles of Brain Tumor Systemic Therapy (BRAIN-D).

Note: All recommendations are category 2A unless otherwise indicated.

Clinical Trials: NCCN believes that the best management of any cancer patient is in a clinical trial. Participation in clinical trials is especially encouraged.

POSTINDUCTION THERAPY

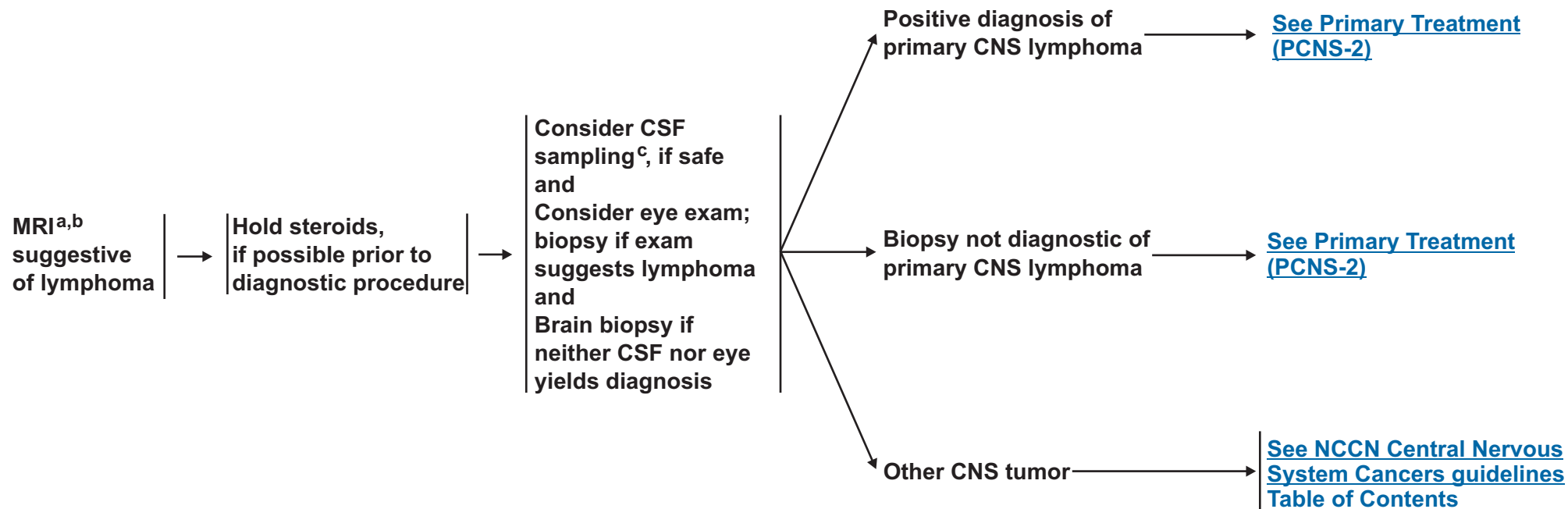


^gSee Principles of Brain Tumor Radiation Therapy (BRAIN-C).

ⁱSee Principles of Brain Tumor Systemic Therapy (BRAIN-D).

Note: All recommendations are category 2A unless otherwise indicated.
Clinical Trials: NCCN believes that the best management of any cancer patient is in a clinical trial. Participation in clinical trials is especially encouraged.

DIAGNOSIS BY
TISSUE EVALUATION



^aBiopsy first if MRI compatible with CNS lymphoma.

^bContrast CT, if patient cannot have MRI.

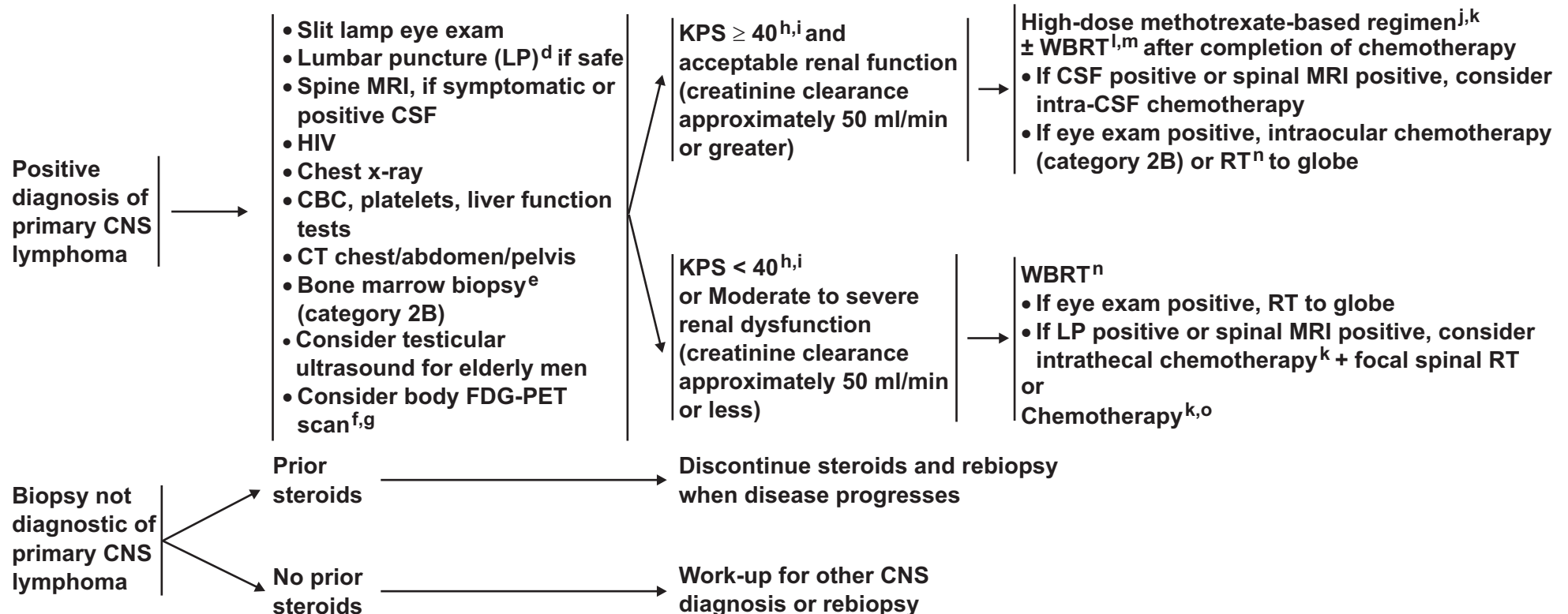
^cTissue sampling and CSF should include flow cytometry, CSF cytology, and may consider gene rearrangements.

Note: All recommendations are category 2A unless otherwise indicated.

Clinical Trials: NCCN believes that the best management of any cancer patient is in a clinical trial. Participation in clinical trials is especially encouraged.

STAGING EVALUATION/WORKUP

PRIMARY TREATMENT



^dCaution is indicated in patients who are anticoagulated, thrombocytopenic, or who have a bulky intra-cranial mass.

^eSome institutions do bone marrow biopsy, however, evidence is lacking.

^fBody PET scan may replace CT, bone marrow, and testicular ultrasound, but data for its use in Primary CNS lymphoma (PCNSL) is lacking.

^gFor full primary CNS lymphoma staging guidelines, refer to Abrey LE, Batchelor TT, Ferreri AJM, et al. Report of an international workshop to standardize baseline evaluation and response criteria for primary CNS lymphoma. J Clin Oncol 2005;23:5034-5043.

^hKPS may improve dramatically with steroids.

ⁱAge and performance status guidelines have not been firmly established and consultation between physician and patient regarding risks and benefits of aggressive therapy is mandatory.

^jParticipation in clinical trials is highly recommended.

^k[See Principles of Brain Tumor Systemic Therapy \(BRAIN-D\).](#)

^lWBRT may increase toxicity, especially in patients > 60 y and may be withheld in the primary setting.

^mIf eye exam positive, monitor carefully for response to treatment. Consider RT to orbits or intraocular chemotherapy.

ⁿ[See Principles of Brain Tumor Radiation Therapy \(BRAIN-C\).](#)

^oConsider alternate chemotherapy regimens for patients who cannot tolerate methotrexate.

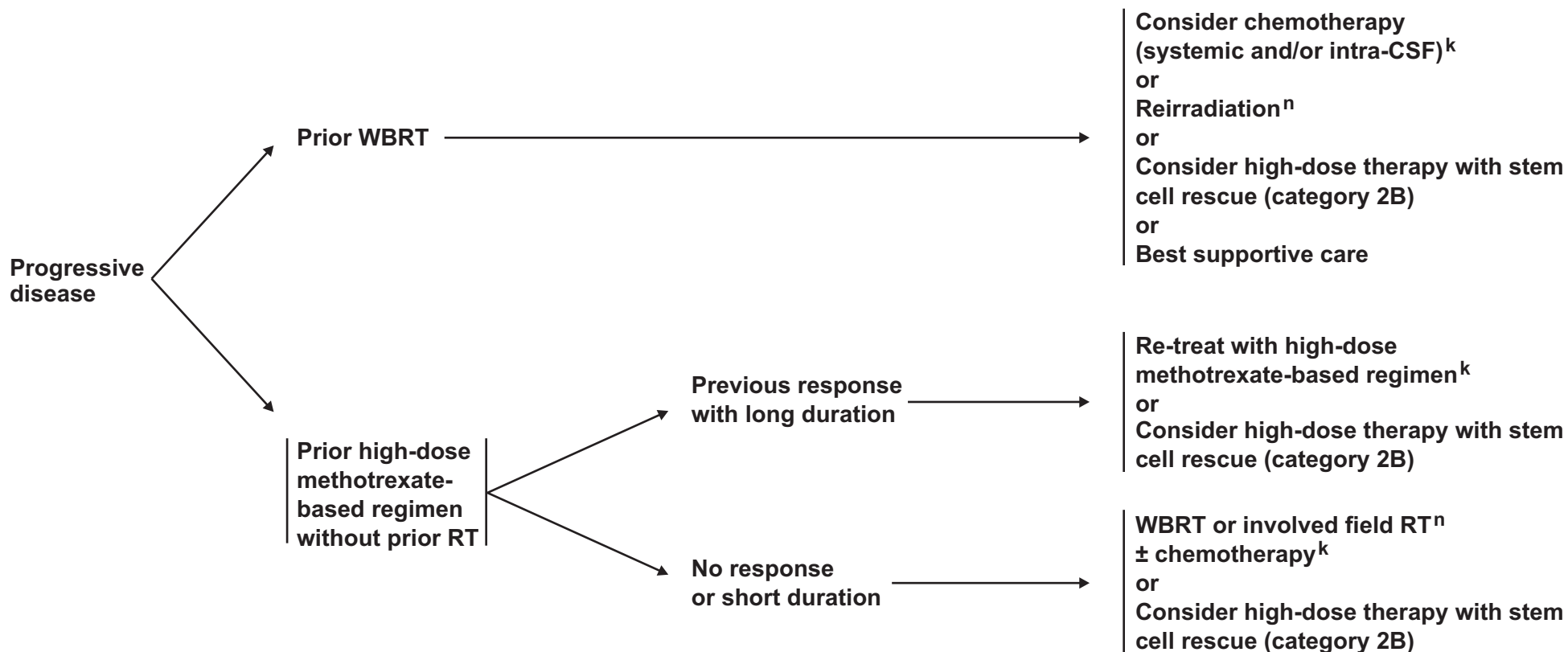
Note: All recommendations are category 2A unless otherwise indicated.

Clinical Trials: NCCN believes that the best management of any cancer patient is in a clinical trial. Participation in clinical trials is especially encouraged.

[See Progressive Disease \(PCNS-3\)](#)

PROGRESSIVE DISEASE

TREATMENT



^kSee Principles of Brain Tumor Systemic Therapy (BRAIN-D).

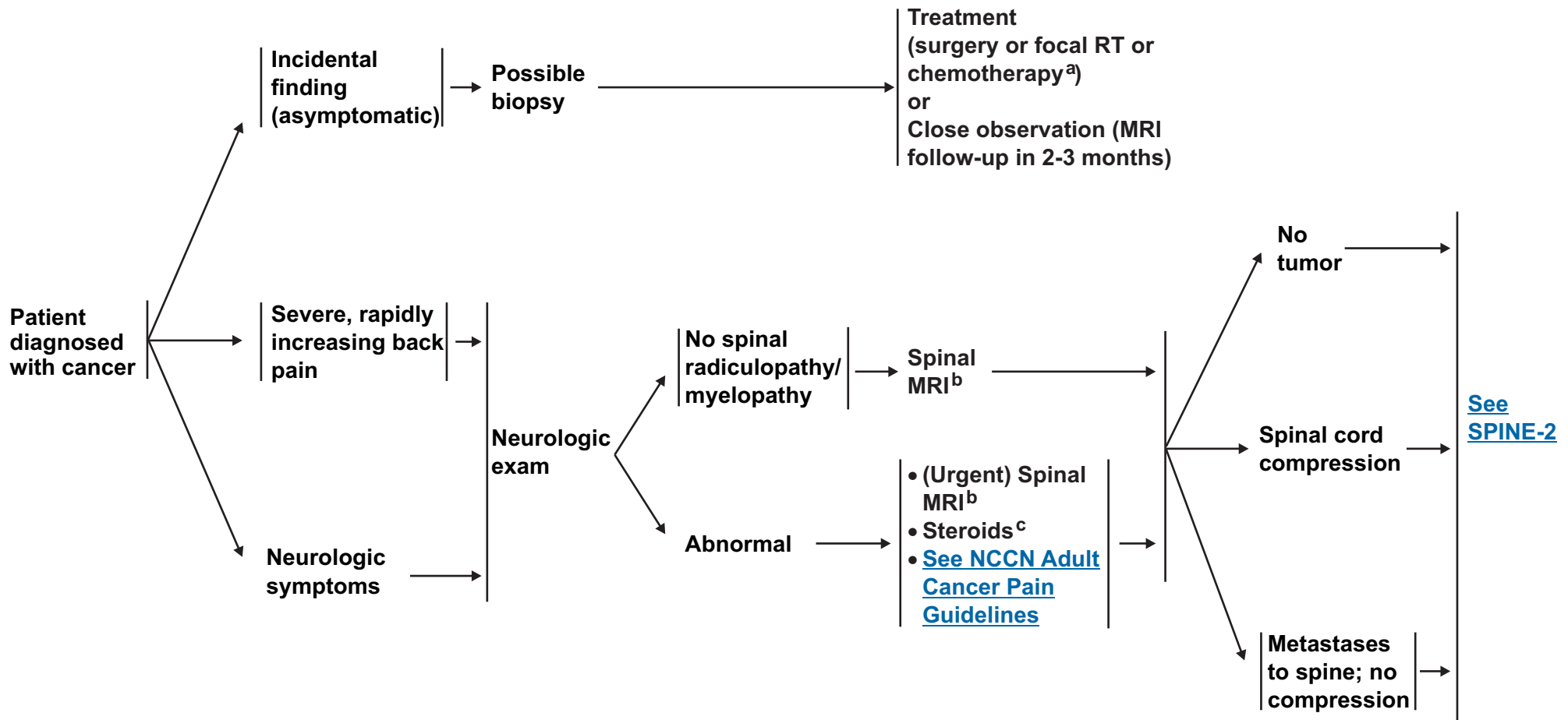
ⁿSee Principles of Brain Tumor Radiation Therapy (BRAIN-C).

Note: All recommendations are category 2A unless otherwise indicated.
Clinical Trials: NCCN believes that the best management of any cancer patient is in a clinical trial. Participation in clinical trials is especially encouraged.

PRESENTATION

WORKUP

TREATMENT



^aSee [Principles of Brain Tumor Systemic Therapy \(BRAIN-D\)](#).

^bIf the patient is unable to have an MRI, then a CT myelogram is recommended.

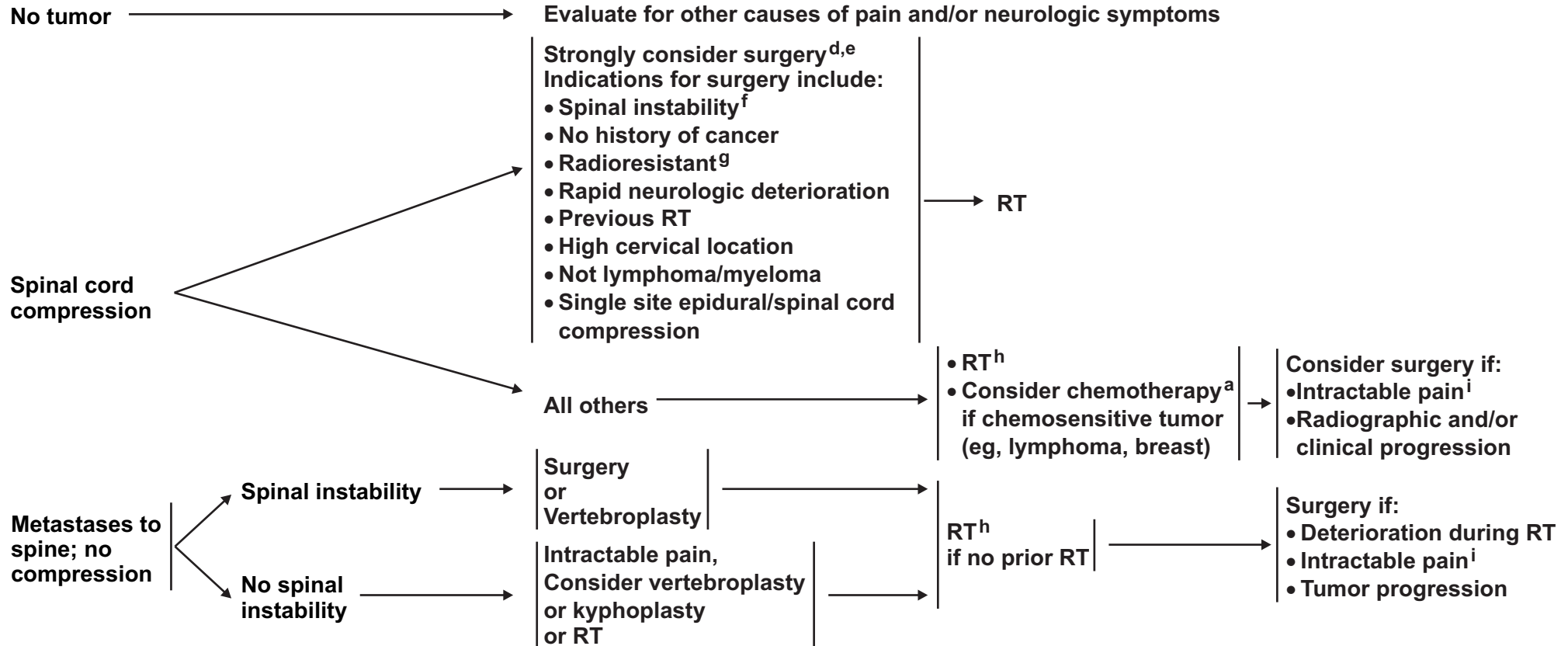
^cThe recommended minimum dose of steroids is 4 mg of dexamethasone every 6 hours, although dose of steroids may vary (10-100 mg). For rapid neurologic deterioration or significant myelopathy, a stat MRI is recommended. A randomized trial supported the use of high-dose steroids (Sorensen PS, Helweg-Larsen S, Mouridsen H, Hansen HH. Effect of high-dose dexamethasone in carcinomatous metastatic spinal cord compression treated with radiotherapy: A randomized trial. Eur J Cancer 1994;30A:22-27).

Note: All recommendations are category 2A unless otherwise indicated.

Clinical Trials: NCCN believes that the best management of any cancer patient is in a clinical trial. Participation in clinical trials is especially encouraged.

PRESENTATION

TREATMENT



^aSee Principles of Brain Tumor Systemic Therapy (BRAIN-D).

^dSurgery could involve tumor resection with or without spinal stabilization. Spinal instrumentation is recommended if there is preoperative spinal instability or if instability is expected to occur after tumor resection.

^eCategory 1 evidence supports the role of surgery in patients willing to undergo surgery. (Patchell RA, Tibbs PA, Regine WF, et al. Direct decompressive surgical resection in the treatment of spinal cord compression caused by metastatic cancer: a randomised trial. Lancet 2005;366(9486):643-648)

^fSpinal instability is grossly defined as the presence of significant kyphosis or subluxation (deformity), or of significantly retropulsed bone fragment.

^gRadioresistant tumors include renal carcinoma, melanoma, or sarcoma.

^hShort RT regimens given over 2-3 weeks or less or consider stereotactic RT.

ⁱIntractable pain can be treated by implantation of a subarachnoid pump, tumor resection/stabilization, or vertebroplasty/kyphoplasty depending on stability, extent of disease, and location in the spinal column.

Note: All recommendations are category 2A unless otherwise indicated.

Clinical Trials: NCCN believes that the best management of any cancer patient is in a clinical trial. Participation in clinical trials is especially encouraged.

PRINCIPLES OF BRAIN TUMOR IMAGING

- **Enhanced MRI of the brain:**
 - ▶ **Gold standard**
 - ▶ **Provides a “static” picture of tumors**
 - ▶ **Benefits: Provides a reasonably good delineation of tumors. Higher grade tumors usually enhance, as does brain leptomeningeal metastasis**
 - ▶ **Limitations: Sensitive to movement, metallic objects cause artifact, patients with implantable devices cannot have an MRI, claustrophobia may be an issue**

- **Enhanced CT of the brain:**
 - ▶ **Should be used in patients who cannot have an MRI**
 - ▶ **Benefits: Claustrophobia or implantable devices are not an issue, can be done faster than an MRI**
 - ▶ **Limitations: Lacks resolution of MRI, especially in posterior fossa**

- **MR Spectroscopy: Assess metabolites within tumors and normal tissue**
 - ▶ **Optimal use is to differentiate tumor from radiation necrosis; may be helpful in grading tumors or assessing response.**
 - ▶ **Area most abnormal would be the best place to target for a biopsy**
 - ▶ **Limitations: Tumors near vessels, air spaces, or bone. Extra time in MRI and others as noted under MRI**

- **MR Perfusion: Measures cerebral blood volume in tumors**
 - ▶ **May be helpful in differentiating grade of tumor or tumor versus radiation necrosis. Area of highest perfusion would be the best place to biopsy.**
 - ▶ **Limitations: Tumors near vessels, air spaces, bone, small volume lesions, or tumors in the spinal cord. Extra time in MRI and others as noted under MRI**

- **Body PET scanning: Assess metabolism within tumor and normal tissue by using radio-labeled tracers**
 - ▶ **Optimal use is differentiating tumor from radiation necrosis but has some limitations; may also correlate with tumor grade or provide the optimal area for biopsy**
 - ▶ **Limitations: Accuracy of interpretations, availability of equipment and isotopes**

This is a list of imaging modalities available and used in neuro-oncology primarily to make treatment decisions. The most common use for MR spectroscopy, MR perfusion, and body PET is to differentiate radiation necrosis from active tumor, as this might obviate the need for surgery or the discontinuation of an effective therapy.

Note: All recommendations are category 2A unless otherwise indicated.

Clinical Trials: NCCN believes that the best management of any cancer patient is in a clinical trial. Participation in clinical trials is especially encouraged.

PRINCIPLES OF BRAIN TUMOR SURGERY

GUIDING PRINCIPLES

- Maximal tumor removal
- Minimal surgical morbidity
- Accurate diagnosis

FACTORS

- Age
- Performance status (PS)
- Feasibility of decreasing the mass effect with surgery
- Resectability, including number of lesions, location of lesions, time since last surgery (recurrent patients)
- New versus recurrent tumor

OPTIONS

- Gross total resection where feasible
- Stereotactic biopsy
- Open biopsy/debulking

TISSUE

- Maximum to pathologist
- Review by experienced neuropathologist

Postoperative MRI should be performed within 24-72 hours to determine the extent of resection

Note: All recommendations are category 2A unless otherwise indicated.

Clinical Trials: NCCN believes that the best management of any cancer patient is in a clinical trial. Participation in clinical trials is especially encouraged.

PRINCIPLES OF BRAIN TUMOR RADIATION THERAPY

Low Grade Gliomas (Grades I/II)

- ▶ Tumor volumes are best defined using pre- and postoperative imaging, usually FLAIR and or T2 signal abnormality on MRI for GTV. CTV (GTV plus 1-2 cm margin) should receive 45-54 Gy in 1.8-2.0 Gy fractions.
- ▶ SRS has not been established to have a role in the management of low grade gliomas. Although it is used selectively in patients who have not had radiotherapy.

Ependymoma

- ▶ **Limited Fields:** Tumor volumes are best defined using pre- and postoperative imaging, usually enhanced T1 and or FLAIR/T2. Anatomic areas touched by preoperative tumor volume plus postoperative signal abnormality on MRI for GTV. CTV (GTV plus 1-2 cm margin) should receive 54-59.4 Gy in 1.8 to 2.0 Gy fractions.
- ▶ **Craniospinal:** Whole brain and spine (to bottom of thecal sac) receive 36 Gy in 1.8 Gy fractions, followed by limited field to spine lesions to 45 Gy. Primary brain site should receive total dose of 54-59.4 Gy in 1.8 to 2.0 Gy fractions.

High Grade Gliomas (Grades III/IV)

- ▶ Tumor volumes are best defined using pre and postoperative imaging, usually enhanced T1 or FLAIR/T2. Attention should also be paid to include anatomically expanded regions likely involved with tumor. A single CTV may be defined as the resection cavity + T1 contrast GTV plus 3 cm. Alternatively a “shrinking field” technique may be used defining GTV1 as FLAIR or T2 signal abnormality and GTV2 as resection cavity + enhanced T1 abnormality. Total doses of 54-60 Gy in 1.8 to 2.0 Gy fractions should be received by GTV2.

Brain Metastases

- ▶ **Whole brain radiotherapy (WBRT):** Doses of 30-45 Gy in 1.8 to 3.0 Gy fractions are recommended depending on patient's performance status.¹
- ▶ **Stereotactic radiosurgery:** Recommend maximum marginal doses of 24, 18, or 15 Gy for targets ≤ 2 cm, 2.1-3 cm or 3.1-4 cm, respectively (RTOG 90-05).^{2,3}

Carcinomatous/Lymphomatous Meningitis

- ▶ Volumes and dose depend on primary source and sites requiring palliation.

Primary CNS Lymphoma

- ▶ WBRT may be withheld in primary setting. When used, WBRT doses should be limited to 24-36 Gy in 1.8-2.0 Gy fractions following a CR to chemotherapy. For less than CR, consider the same WBRT dose followed by a limited field to gross disease to 45 Gy.
- ▶ Lower doses of radiation are less toxic and may be as effective.

Metastatic Spine

- ▶ Doses to vertebral body metastases will depend on patient's performance status and primary histology. Generally doses of 30-37.5 Gy are delivered in 10-15 fractions over 2-3 weeks.

CR: Complete response
CTV: Clinical target volume
FLAIR: Fluid-attenuated inversion recovery
GTV: Gross tumor volume

¹ Andrews DW, Scott CB, Sperduto PW, et al. Whole brain radiation therapy with or without stereotactic radiosurgery boost for patients with one to three brain metastases: phase III results of the RTOG 9508 randomised trial. *Lancet* 2004;363(9422):1665-1672.

² Shaw E, Scott C, Souhami L, et al. Single dose radiosurgical treatment of recurrent previously irradiated primary brain tumors and brain metastases: final report of RTOG protocol 90-05. *J Radiat Oncol Biol Phys* 2000;47(2):291-298.

³ Aoyama H, Shirato H, Tago M, et al. Stereotactic radiosurgery plus whole-brain radiation therapy vs stereotactic radiosurgery alone for treatment of brain metastases: A randomized controlled trial. *JAMA* 2006;295(21):2483-2491.

Note: All recommendations are category 2A unless otherwise indicated.

Clinical Trials: NCCN believes that the best management of any cancer patient is in a clinical trial. Participation in clinical trials is especially encouraged.

PRINCIPLES OF BRAIN TUMOR SYSTEMIC THERAPY (1 of 3)**Adult Low-Grade Infiltrative Supratentorial Astrocytoma/
Oligodendroglioma (excluding pilocytic astrocytoma)**

- **Adjuvant Treatment:**
 - ▶ Temozolomide 150-200 mg/m² 5/28 schedule¹
- **Recurrence or Progressive, low grade disease:**
 - ▶ **First Line:**
 - ◊ Temozolomide* 5/28 schedule
 - ▶ **Second Line:**
 - ◊ Nitrosourea[†] alone (carmustine [BCNU] 210 mg/m² IV every 6 weeks or 80 mg/m² daily x 3 every 6 weeks, lomustine [CCNU] 110mg /m² PO every 6 weeks)
 - ◊ Combination PCV (CCNU + procarbazine + vincristine)

**Adult Intracranial Ependymoma
(excluding subependymoma and myxopapillary)**

- **Recurrence**
 - ▶ Etoposide
 - ▶ Temozolomide
 - ▶ Nitrosourea²
 - ▶ Platinum-based regimens:^α Single agent or combination

*For patients not previously treated.

†Addition of CCNU and procarbazine.

^αPlatinum-based regimens include cisplatin or carboplatin.**Glioblastoma Multiforme**

- **Adjuvant Treatment:**^{3,4}
 - ▶ Concurrent temozolomide¹ 75 mg/m² daily
 - ▶ Adjuvant temozolomide 150-200 mg/m² 5/28 schedule
- **Recurrence/Salvage therapy**
 - ▶ Temozolomide¹
 - ▶ Bevacizumab ± irinotecan^{5,6,7,8}
 - ▶ Nitrosoureas²
 - ▶ Combination PCV
 - ▶ Platinum-based regimens^α (second- or third-line therapy)

**Anaplastic Astrocytoma/Anaplastic Oligodendroglioma
(also includes mixed anaplastic oligoastrocytoma)**

- **Adjuvant Treatment:**^{3,4}
 - ▶ Consider temozolomide¹ or nitrosourea
- **Combined Chemoradiation (category 3)**
 - ▶ Concurrent temozolomide 75 mg/m² daily
- **Recurrence/Salvage therapy**
 - ▶ Temozolomide⁹
 - ▶ Bevacizumab ± irinotecan^{5,6,8}
 - ▶ Nitrosoureas²
 - ▶ Combination PCV¹⁰
 - ▶ Irinotecan
 - ▶ Platinum-based regimens^{11,12, α} (second- or third-line therapy)

[See references on page 3 of 3 BRAIN-D](#)[See Additional Chemotherapy Regimens 2 of 3 BRAIN-D](#)**Note:** All recommendations are category 2A unless otherwise indicated.**Clinical Trials:** NCCN believes that the best management of any cancer patient is in a clinical trial. Participation in clinical trials is especially encouraged.

PRINCIPLES OF BRAIN TUMOR SYSTEMIC THERAPY (2 of 3)Limited (1-3) Metastatic or Multiple (> 3) Metastatic Lesions• Recurrent Disease[‡]

- Treatment as per the regimens of the primary tumor
- Temozolomide 5/28 schedule (organ specific therapy)
- Capecitabine, high dose methotrexate, cyclophosphamide (breast¹³ and lymphoma)
- Cisplatin, etoposide (breast)
- Topotecan (lung)

Carcinomatous/Lymphomatous Meningitis

• Treatment

- Organ specific systemic chemotherapy; emphasizing drugs with good CNS penetration
- Intra-CSF chemotherapy (liposomal cytarabine,¹⁴ methotrexate, cytarabine, thiotepa)
- High-dose methotrexate for lymphomatous meningitis¹⁵

Primary CNS Lymphoma (Nonimmunosuppressed)

• Primary Treatment

- High dose methotrexate 3.5 g/m² or higher as single agent or in combination

• Recurrence or Progressive Disease

- Retreat with high-dose methotrexate
- Rituximab with temozolomide
- Rituximab
- Topotecan
- Consider HDT with stem cell rescue
- Temozolomide
- MVP (methotrexate, vincristine, procarbazine, consolidation cytarabine)¹⁶

Metastatic Spine Tumors

• Use regimen for disease specific site

[‡]Use agents active against primary tumor.

Note: All recommendations are category 2A unless otherwise indicated.

Clinical Trials: NCCN believes that the best management of any cancer patient is in a clinical trial. Participation in clinical trials is especially encouraged.

[References on
next page](#)

PRINCIPLES OF BRAIN TUMOR SYSTEMIC THERAPY (3 of 3)
(References)

- ¹5/28 schedule: Stupp R, Mason WP, van den Bent MJ, et al; European Organisation for Research and Treatment of Cancer Brain Tumor and Radiotherapy Groups; National Cancer Institute of Canada Clinical Trials Group. Radiotherapy plus concomitant and adjuvant temozolomide for glioblastoma. *N Engl J Med* 2005;352(10):987-996.
- ²Brem H, Piantadosi S, Burger PC, Walker M, Selker R, et al. Placebo-controlled trial of safety and efficacy of intraoperative controlled delivery by biodegradable polymers of chemotherapy for recurrent gliomas. *The Lancet* 1995;345: 1008-1012.
- ³Stewart LA: Chemotherapy in adult high-grade glioma: A systemic review and meta-analysis of individual patient data from 12 randomized trials. *Lancet* 2002;359:1011-1018.
- ⁴Fine HA, Dear KB, Loeffler JS, et al: Meta-analysis of radiation therapy and without chemotherapy for malignant gliomas in adults. *Cancer* 1993;71:2585-2597 .
- ⁵Vredenburgh JJ, Desjardins A, Herndon JE, II, et al. Bevacizumab plus irinotecan in recurrent glioblastoma multiforme. *J Clin Oncol* 2007;25(30):4722-4729.
- ⁶Norden AD, Young GS, Setayesh K, et al. Bevacizumab for recurrent malignant glioma: efficacy, toxicity and patterns of recurrence. *Neurology*. 2008;70:779-787.
- ⁷Cloughesy T, Prados MD, Mikkelsen T, et al. A phase 2 randomized non-comparative clinical trial of the effect of bevacizumab alone or in combination with irinotecan on 6-month progression free survival in recurrent treatment refractory glioblastoma. *J Clin Oncol*. 2008;26:91s (Abstract).
- ⁸Vredenburgh JJ, Desjardins A, Herndon JE II, Dowell JM, Reardon DA, Quinn JA, et al. Phase II trial of bevacizumab and irinotecan in recurrent malignant glioma. *Clin Cancer Res*. 2007;13(4):1253-1259.
- ⁹Yung WK, Prados MD, et al., Multicenter phase II trial of temozolomide in patients with anaplastic astrocytoma or anaplastic oligoastrocytoma at first relapse. Temodal Brain Tumor Group. *J Clin Oncol* 1999;17:2762-2771 .
- ¹⁰Triebels VH, Taphoorn, Brandes AA, et al. Salvage PCV chemotherapy for temozolomide resistant oligodendrogliomas. *Neurology* 2004;63: 904-906.
- ¹¹Soffieti R, Nobile M, Rida F, et al. Second-line treatment with carboplatin for recurrent or progressive oligodendroglial tumors after PCV chemotherapy: a phase II study. *Cancer* 2004;15:807-813.
- ¹²Brandes AA, Basso U, Vastola F, et al. Carboplatin and teniposide as third-line chemotherapy in patients with recurrent oligodendroma or oligoastrocytoma: a phase II study. *Ann Oncol* 2003;14:1727-1731.
- ¹³Lassman AB, Abrey LE, Shah GD, et al. Systemic high-dose intravenous methotrexate for central nervous system metastases. *J Neurooncol* 2006;78(3):255-260.
- ¹⁴Jaekle KA, Phuphanich S, Bent MJ, et al. Intrathecal treatment of neoplastic meningitis due to breast cancer with a slow-release formulation of cytarabine. *Br J Cancer* 2001;84(2):157-163.
- ¹⁵Bokstein F, Lossos A, Lossos IS, Siegal T, Central nervous system relapse of systemic non-Hodgkin's lymphoma: results of treatment based on high-dose methotrexate combination chemotherapy, *Leuk Lymphoma* 2002;43(3):587-593.
- ¹⁶Gavrilovic IT, Hormigo A, Yahalom J, et al. Long-term follow-up of high-dose methotrexate-based therapy with and without whole brain irradiation for newly diagnosed primary CNS lymphoma. *J Clin Oncol* 2006;24(28):4570-4574.

Note: All recommendations are category 2A unless otherwise indicated.

Clinical Trials: NCCN believes that the best management of any cancer patient is in a clinical trial. Participation in clinical trials is especially encouraged.

Manuscript

This manuscript is being updated to correspond with the newly updated algorithm. Last updated 02/27/08

NCCN Categories of Evidence and Consensus

Category 1: The recommendation is based on high-level evidence (e.g. randomized controlled trials) and there is uniform NCCN consensus.

Category 2A: The recommendation is based on lower-level evidence and there is uniform NCCN consensus.

Category 2B: The recommendation is based on lower-level evidence and there is nonuniform NCCN consensus (but no major disagreement).

Category 3: The recommendation is based on any level of evidence but reflects major disagreement.

All recommendations are category 2A unless otherwise noted.

Overview

In the year 2008, an estimated 21,810 new cases of primary brain and other nervous system neoplasms will be diagnosed in the United States. These tumors will be responsible for approximately 13,070 deaths.¹ The incidence of primary malignant brain tumors has been increasing over the last 30 years, especially in elderly persons (rates are increasing at about 1.2% each year).² Metastatic disease to the central nervous system (CNS) occurs much more frequently, with an incidence about 10 times that of primary brain tumors. It is estimated between 20% and 40% of patients with systemic cancer will develop brain metastases.

Primary and metastatic brain tumors are a heterogeneous group of neoplasms with varied outcomes and management strategies. Primary brain tumors range from pilocytic astrocytomas (which are very

uncommon, noninvasive, and surgically curable) to glioblastoma multiforme, the most common intraparenchymal brain tumor in adults, which is highly invasive and virtually incurable. Likewise, patients with metastatic brain disease may have rapidly progressive systemic disease or no systemic cancer at all. These patients may have one or dozens of brain metastases, and they may have a malignancy that is highly responsive or, alternatively, highly resistant to radiation or chemotherapy. Because of this marked heterogeneity, the prognostic features and treatment options for brain tumors must be carefully reviewed for each patient. The involvement of an interdisciplinary team (including neurosurgeons, radiation therapists, oncologists, neurologists, or neuroradiologists) is a key factor in the appropriate management of these patients. These NCCN CNS Cancers guidelines focus on management of adults with CNS cancers.

Treatment Principles

Several important principles guide surgical and radiation therapy (RT) for adults with primary brain tumors. Regardless of tumor histology, neurosurgeons generally provide the best outcome for their patients if they remove as much tumor as possible, keep surgical morbidity to a minimum, and ensure an accurate diagnosis. Decisions regarding aggressiveness of surgery for a primary brain tumor are complex and depend on the (1) age and performance status (PS) of the patient; (2) proximity to “eloquent” areas of the brain; (3) feasibility of decreasing the mass effect with aggressive surgery; (4) resectability of the tumor (including the number and location of lesions); and (5) in patients with recurrent disease, the time since the last surgery.³

The surgical options include stereotactic biopsy, open biopsy or debulking procedure, subtotal resection, or gross total tumor resection where feasible. The pathologic diagnosis is critical and often difficult to determine accurately; therefore, as much tissue as possible should be delivered to the pathologist. Review by an experienced

neuropathologist is highly recommended. In addition, a postoperative magnetic resonance imaging (MRI) scan, with and without contrast, should be obtained 24 to 72 hours after surgery to document the extent of disease after surgical intervention.

Radiation oncologists use several different treatment approaches in patients with primary brain tumors, including brachytherapy, stereotactic fractionated RT, and stereotactic radiosurgery. Fractionated external beam radiation is the most common approach. RT for patients with primary brain tumors usually involves only the tumor volume and margins. Clinical target volume is commonly defined as the region showing T2-weighted abnormalities on an MRI scan plus a 1 to 2 cm margin. The dose of radiation administered varies depending on the pathology.

Tumor Types

The NCCN CNS Cancer Guidelines focus on high-grade invasive astrocytomas (including glioblastoma multiforme), low-grade invasive astrocytomas, oligodendrogliomas, ependymomas, brain metastases, carcinomatous/lymphomatous meningitis, primary CNS lymphoma (non-AIDS), and metastatic spinal tumors. These guidelines are updated annually to include new information or treatment philosophies as they become available. However, because this field changes continually, practitioners should use all of the available information to determine the best clinical options for their patients with primary or metastatic brain tumors.

High-Grade Invasive Astrocytomas

Grade III (anaplastic astrocytoma) and grade IV (glioblastoma multiforme) astrocytomas are the most common primary brain tumors in adults and account for 2.3% of all cancer-related deaths. Glioblastoma multiforme tumors account for more than 50% of all gliomas, and 8000 to 10,000 new cases are diagnosed per year in North America; peak

incidence occurs from ages 45 to 55 years. The high-grade astrocytomas diffusely infiltrate surrounding tissues and frequently cross the midline to involve the contralateral brain. Patients with these neoplasms often present with symptoms of increased intracranial pressure, seizures, or focal neurologic findings related to the size and location of the tumor and to associated peritumoral edema. These tumors usually do not have associated hemorrhage or calcification but produce considerable edema and mass effect in image study as well as enhance after the administration of intravenous contrast. Tumor cells have been found in the peritumoral edema, which corresponds to the T2-weighted MRI abnormalities. As a result, this volume is frequently used to define radiation treatment portals.

It is difficult to assess the results of therapy using computerized tomographic (CT) scans or MRI scans, because the extent and distribution of contrast enhancement, edema, and mass effect are more a function of blood-brain barrier integrity than of changes in the size of the tumor. Thus, other factors that exacerbate blood-brain barrier dysfunction (such as surgery, radiation, and tapering of corticosteroids) can mimic tumor progression by increasing contrast enhancement, T2-weighted abnormalities, and mass effect. The most important prognostic factors in patients with high-grade astrocytomas are histologic diagnosis, age, PS, type and duration of symptoms, and extent of surgical resection.⁴

Treatment Overview

The goals of surgery are to obtain a diagnosis, alleviate symptoms related to increased intracranial pressure or compression, increase survival, and decrease the need for corticosteroids. The median survival with surgery alone is approximately 4 months. A prospective study in patients with malignant glioma showed that extensive surgery was valuable when compared with biopsy alone as a strong prognostic factor.⁵ Most studies suggest that the extent of resection lengthens

survival and is especially effective in patients older than 50 years with glioblastoma multiforme and a Karnofsky performance score (KPS) more than 70. Using current microneurosurgical techniques, it is possible to resect malignant gliomas in gross total fashion. An aggressive approach in which 98% or more of the tumor mass is resected results in a statistically significant survival advantage.⁶ Surgery also improves the outcome for patients with recurrent high-grade astrocytomas.⁷

Fractionated external beam RT is standard therapy for patients with high-grade astrocytomas after either maximal excision or biopsy. Use of RT is based on a randomized trial conducted in the 1970s comparing postoperative supportive care, carmustine (BCNU), radiation, and radiation plus BCNU.⁸ Survival at 1 year was 3% with surgery alone, 12% with postoperative BCNU, and 24% with postoperative radiation. Total doses of 54-60 Gy (in 1.8 to 2.0 Gy fractions) are administered to the gross tumor volume (GTV2). Use of abbreviated courses of radiation in older patients may be considered but has not been studied in combination with modern chemotherapy.⁹ Alternative dose--fractionation schedules have been explored without significant improvement in adult patients with malignant gliomas. The role of focal radiation techniques in this diffusely infiltrative disease remains undefined.

The Radiation Therapy Oncology Group (RTOG) conducted a randomized trial of conventional radiotherapy to 60 Gy and BCNU alone or preceded by a radiosurgery boost (to 15-24 Gy) in patients with glioblastoma multiforme of 4 cm or less.¹⁰ However, the results were disappointing with no improvement in local control or survival with stereotactic radiosurgery boost. Similarly, a trial done at Princess Margaret Hospital randomly assigned patients to 50 Gy external beam radiation with or without temporary I-125 seed implant to 60 Gy; however, this trial did not show any survival benefit.¹¹

Traditionally, chemotherapy was felt to be of marginal value in the treatment of newly diagnosed patients with high-grade gliomas. Walker and colleagues did a randomized study of (1) a nitrosourea alone, versus (2) radiation alone, versus (3) radiation plus a nitrosourea.¹² Although a slight improvement in survival was noted at 18 months in the group of patients who were treated with radiation plus BCNU compared with those who had received radiation alone, the difference in survival curves between the 2 groups was not statistically significant. More than 20 years later (2001), the Medical Research Council reported results from the largest randomized trial of adjuvant chemotherapy in high-grade gliomas.¹³ In this study, 674 patients were randomly assigned either to radiation alone or to radiation plus PCV (procarbazine, lomustine [CCNU], and vincristine). No survival benefit was seen with the addition of PCV, even in patients with anaplastic astrocytomas.

In contrast, 2 meta-analyses reviewed data from randomized trials of high-grade glioma patients, and both found a modest survival benefit when chemotherapy was added to postoperative radiation.^{14,15} Specifically, in the meta-analysis (GMT Group, 2002) of 12 studies involving approximately 3000 patients with high-grade gliomas who were treated either with postoperative radiation alone or with radiation plus chemotherapy, there was an absolute increase in 1-year survival from 40% to 46% and a 2-month increase in median survival when chemotherapy was added to postoperative radiation.¹⁵

Most of these trials studied nitrosourea-based chemotherapy regimens. Temozolomide, a newer drug that is classified as an atypical alkylating agent, received U.S. Food and Drug Administration (FDA) approval for the treatment of patients newly diagnosed with glioblastoma multiforme in March 2005. Temozolomide received accelerated FDA approval for recurrent anaplastic astrocytomas in 1999; however, the accelerated approval requirements no longer apply. In Europe, temozolomide's

approved indication is for the treatment of both recurrent anaplastic astrocytoma and recurrent glioblastoma multiforme. A phase III, randomized study assessed temozolomide in 573 patients with glioblastoma multiforme who received either (1) daily temozolomide (75 mg/m²) administered with postoperative RT followed by 6 cycles of adjuvant temozolomide (150-200 mg/m²/day given 5 days during each 28-day cycle); or (2) radiotherapy alone.¹⁶ Temozolomide resulted in a statistically better median survival (14.6 versus 12.1 months) and 2-year survival (26.5% versus 10.4%) when compared with RT.¹⁶ However, the design of this study does not shed light on what is responsible for the improvements in survival: the temozolomide administered with radiation, following radiation, or both. Subsequent analyses suggest that MGMT (O-6-methylguanine-DNA methyltransferase) status may determine which patients obtain benefit from adjuvant temozolomide therapy.¹⁷ MGMT (a DNA repair enzyme) may cause resistance to DNA-alkylating drugs commonly used in the treatment of anaplastic oligodendrogliomas and other malignant gliomas.¹⁸ Note that side effects for temozolomide include nausea, vomiting, headaches, fatigue, and anorexia. Prophylaxis against *Pneumocystis carinii* pneumonia (PCP) is required when temozolomide is administered with radiotherapy (<http://www.fda.gov/cder/foi/label/2006/021029s012lbl.pdf>). In elderly patients with glioblastoma multiforme, temozolomide alone may be useful to avoid side effects with RT (for example, excessive fatigue and frequent worsening of neurologic deficits).¹⁹ However, in elderly patients with good PS, adjuvant chemotherapy and RT may be useful.²⁰

In terms of adjuvant treatment for anaplastic astrocytomas, the PCV regimen has commonly been used, in large part, based on the results of a phase III trial that compared BCNU to PCV following RT in patients with high-grade gliomas.²¹ This study found a survival benefit for patients with anaplastic astrocytomas who received PCV. However, a subsequent retrospective analysis determined that there is little

difference between PCV and BCNU.²² Additionally, the Medical Research Council study (2001) previously discussed found no improvement in survival when patients with anaplastic astrocytomas were treated with PCV.¹³ There are no published data directly comparing the benefit of postoperative chemotherapy with temozolomide to a nitrosourea in patients with newly diagnosed anaplastic astrocytomas. This study is currently underway through the RTOG (9813); however, no results have been reported yet. Given the better side-effect profile of temozolomide and the positive results of the phase III trial reported by Stupp and colleagues, temozolomide is recommended (category 1) for postoperative chemotherapy in patients with glioblastoma multiforme.¹⁶

Unfortunately, currently available chemotherapy does not provide cures in any of these patients. In addition to temozolomide and the nitrosoureas, agents that also have some activity against gliomas and are commonly used as second-line chemotherapy include procarbazine, irinotecan, cisplatin, and carboplatin, platinum-based regimens, or combination PCV.^{23,24} Many other agents are currently being studied. For chemotherapy-naïve patients with glioblastoma multiforme who experience recurrence or progression, temozolomide and cisplatin may be useful.²⁵ Bevacizumab with irinotecan was recently shown to be useful for recurrent glioblastoma multiforme in a phase II trial; overall survival at 6 months was 77%.²⁶

Other routes of drug delivery have been evaluated. Local administration of BCNU using a biodegradable polymer (Gliadel wafer) placed intraoperatively in the surgical cavity has demonstrated a statistically significant improvement in survival for patients with recurrent high-grade gliomas.²⁷ As a result, the FDA approved the Gliadel wafer for this indication. A study in 32 patients with malignant glioma showed a statistically significant prolongation of survival when BCNU polymer was used as initial therapy in combination with RT.²⁸ A phase III trial of

the Gliadel wafer compared to placebo in newly diagnosed patients (240) with malignant glioma also found a statistically significant improvement in median survival from 11.6 months in the placebo group to 13.9 months in the BCNU-wafer treated group.²⁹ This benefit was maintained 2 and 3 years after implantation.²⁸⁻³⁰ On the basis of these studies, the FDA extended the approval of BCNU polymer wafers for use in malignant gliomas as initial therapy (February 2003). The European regulatory agencies similarly extended their approval to its initial use in October 2004.

Patients with primary brain tumors or brain metastases frequently take medications to control seizures. Some of the more commonly used anticonvulsants, such as phenytoin and carbamazepine, are known to induce the hepatic cytochrome P450 isoenzyme system. Induction of these hepatic enzymes can enhance clearance of concurrently administered drugs that are eliminated by hepatic oxidative metabolism, resulting in lower blood levels of a drug and decreased efficacy. Hepatic enzyme-inducing anticonvulsants (HEIAs) have been shown to dramatically affect the pharmacology of some chemotherapy agents,³¹⁻³⁵ such as irinotecan³⁶ and paclitaxel.³⁷ As a result, a patient who is taking an HEIA will require a higher than standard dose of these particular chemotherapy agents in order to obtain therapeutic plasma levels. One way to avoid this problem is to switch the patient to a non-HEIA, such as gabapentin, lamotrigine, or levetiracetam.

Treatment Algorithm

The NCCN Panel wrote a treatment algorithm for patients with newly diagnosed and recurrent high-grade astrocytomas (including mixed anaplastic oligoastrocytomas) using the previous information. When a patient presents with a clinical and radiologic picture suggestive of a high-grade astrocytoma, neurosurgical input is needed regarding the maximal feasible tumor resection. The patient should receive a biopsy first if the MRI is suggestive of CNS lymphoma. Whenever possible,

major tumor removal should be performed; subtotal resection is done if maximal safe resection is not feasible. If high-grade glioma is supported by frozen section diagnosis, BCNU wafer is also recommended (category 2B). The extent of tumor debulking should be documented with an immediate postoperative MRI scan within 72 hours after surgery with and without contrast. If major tumor removal is deemed too risky, a stereotactic or open biopsy or subtotal resection should be performed to establish the diagnosis.

After surgical intervention, patients can be treated with or without BCNU wafer followed by fractionated external beam RT with or without chemotherapy (category 1 for anaplastic oligodendroglioma and category 2B for anaplastic astrocytoma). For anaplastic oligodendroglioma, there are 2 randomized trials that show that adjuvant PCV chemotherapy prolonged progression free survival in patients with combined 1p19q deletions.^{38,39} For patients with good PS who have glioblastoma multiforme, a high level of evidence¹⁶ supports the use of daily temozolomide (75 mg/m²) administered with postoperative RT followed by 6 months of temozolomide (150-200 mg/m²/day times 5 days each month). If there is a prolonged delay in tumor recurrence and a second-stage surgery is required, then the BCNU wafers can be re-inserted because they are biologically active for only 3 weeks, although remnants can be visualized on MRI for up to 1 year. The BCNU wafers can be used as local chemotherapy to avoid systemic toxicity of oral or parental chemotherapy, because there is no detectable blood level of BCNU when the wafer is applied. Alternatively, the wafer can be used to help prevent local tumor recurrence (which occurs in approximately 90% of patients with glioblastoma) in combination with systemic chemotherapy.

Currently, temozolomide is often administered to patients with glioblastoma multiforme and anaplastic astrocytoma, although BCNU, CCNU, or PCV can be used to treat anaplastic astrocytoma.⁴⁰ Young

patients with good PS and lower-grade tumors probably benefit more from chemotherapy than do poorer prognostic groups.

Oligodendrogliomas, particularly those that have chromosomal loss of 1p or combined 1p19q loss, have been reported to be especially sensitive to alkylator chemotherapy.⁴¹ Temozolomide or nitrosourea based chemotherapy regimens may be appropriate. Thus, testing for 1p19q markers can be done if available. Patients should be followed closely with serial MRI scans (at 2-6 weeks and then every 2-3 months for 2-3 years) after the completion of fractionated external beam RT. Because RT can produce additional blood-brain barrier dysfunction, corticosteroid requirements may actually increase; therefore, scans may appear worse during the first 3 months after completion of RT, even though there is no actual tumor progression. Early MRI scans allow for appropriate titration of corticosteroid doses, depending on the extent of mass effect and brain edema. Later scans are used to identify tumor recurrence. Early detection of recurrence is warranted, because local and systemic treatment options are available for patients with recurrent disease. However, MR spectroscopy, MR perfusion, or PET can be considered to rule out radiation necrosis.

When recurrent disease is detected, management depends on the patient's age, PS, histology, response to initial therapy, time since original diagnosis, and whether the recurrence is local or more diffuse. If the tumor appears to be local, repeat resection can be done, with or without a BCNU-impregnated wafer placed locally in the surgical bed; further options depend on whether BCNU was used. If the local recurrence is unresectable or surgery is deemed too risky, systemic chemotherapy (using temozolomide or nitrosourea-based regimens) can be administered or reirradiation can be considered. For diffuse or multiple recurrent disease, systemic chemotherapy is recommended.^{42,43} Best supportive care should also be strongly considered, especially if the patient has a poor PS. Surgery can be an option for a symptomatic large lesion. A response to further

chemotherapy is unlikely after 2 consecutive agents have failed to produce a response.

Low-Grade Invasive Astrocytomas

Low-grade astrocytomas are a diverse group of relatively uncommon malignancies, and outcomes depend on many factors. Of these malignancies, 70% are diffuse astrocytomas (fibrillary, protoplasmic, and gemistocytic types), which are poorly circumscribed, invasive, and gradually evolve into higher-grade astrocytomas. Gliomatosis cerebri is characterized by widespread dissemination of neoplastic astrocytes, often involving an entire cerebral hemisphere. The most common noninfiltrative astrocytomas are the pilocytic astrocytomas, which are circumscribed, often surgically resectable, and rarely transform; however, the NCCN algorithm does not encompass pilocytic astrocytomas because these tumors are curable by surgery alone.

These are more common in the cerebellum of children but also occur in the cerebral cortex of adults. Many other rare low-grade astrocytomas also exist, such as the pleomorphic xanthoastrocytoma, subependymal giant cell astrocytoma, and subependymoma.

Patients with infiltrative low-grade tumors usually present with seizures (66%), headache, and/or weakness. The median duration from onset of symptoms to diagnosis ranges from 6 to 17 months. The mean age at presentation for these tumors is 37 years. The most powerful predictor of survival is age. The average 10-year survival rate for children is 83%, whereas the median survival is only 5 years for those older than 40 years. Other important prognostic factors for survival include long duration of symptoms, excellent postoperative neurologic status, and diploid tumors with a low labeling index. These tumors typically are nonenhancing, low-attenuation lesions on CT scans and MRI scans. However, the imaging "diagnosis" of low-grade astrocytoma is incorrect about 25% of the time; the most common alternate diagnosis is anaplastic astrocytoma.

Treatment Overview

Although low-grade astrocytomas are commonly thought to be benign, most of these tumors behave aggressively despite surgery and fractionated external beam RT.⁴⁴ A low-grade astrocytoma can transform into a glioblastoma during a period of 5 to 10 years.² The best management strategy for a patient with seizures and a probable low-grade astrocytoma has yet to be defined.⁴⁵ Whenever possible, total removal should be attempted, because survival and recurrence-free intervals are superior when the tumors can be safely removed.⁴⁶⁻⁴⁸ Furthermore, a gross total removal could potentially delay or prevent malignant progression.⁴⁹ Of course, for tumors that are infiltrative and involve eloquent areas, a total removal may not be feasible and an aggressive approach could result in neurologic deficits.

Surgery remains an important diagnostic and therapeutic modality for patients with low-grade astrocytomas. The primary surgical goal is to provide adequate tissue for a pathologic diagnosis and grading. Needle biopsies are often performed when lesions are in deep or critical regions of the brain. Biopsy results can be misleading, because gliomas often have varying degrees of cellularity, mitoses, or necrosis from one region to another; thus, small samples can provide a lower histologic grade.

The role of gross total surgical tumor excision in low-grade astrocytomas remains unresolved, although most of the available retrospective biomedical literature suggests a survival benefit from aggressive surgical resection.⁴⁶⁻⁴⁸ Because these tumors are relatively uncommon, published series generally include patients treated for decades, which introduces additional variables. In the past, for example, the completeness of surgical excision was based on the surgeon's report. This approach is relatively unreliable when compared with assessment by modern postoperative imaging studies. Furthermore, most patients also received RT, and thus the net effect of

the surgical procedure on outcome is difficult to evaluate. Shaw and colleagues reviewed 126 patients with astrocytomas and mixed oligoastrocytomas.⁴⁴ After gross total removal, patient survival rates were 52% at 5 years and 23% at 10 years. These survival rates were identical to those after subtotal removal or biopsy only. Most patients received postoperative RT, but a higher proportion in the subtotal removal group received this treatment. This experience suggests that if RT is applied, the degree of surgical removal may be less important. Other studies have suggested prolonged survival in patients who underwent gross total resection, compared with those patients who underwent less radical excision.^{46,47} Berger and colleagues have shown an inverse correlation between the postsurgical residual tumor volume and the length of survival in patients with low-grade astrocytomas.⁵⁰

Biological considerations also favor an attempt at a complete excision of an astrocytoma. First, the tumor may contain higher-grade foci, which may not be reflected in a small specimen. Second, complete excision may decrease the risk of future dedifferentiation to a more malignant astrocytoma.⁴⁹ Third, a large tumor burden is removed, which also may enhance the effect of RT. As a result of these considerations, the general recommendation for treating an astrocytoma is to first attempt as complete an excision of tumor as possible without compromising function.

No consensus exists regarding the proper timing of postoperative radiation in low-grade astrocytomas. Some oncologists advocate immediate fractionated external beam RT, whereas others delay radiation until tumor progression is evident. In Shaw's study (1989), immediate RT did prolong survival in patients with these tumors.⁴⁴ Also, higher doses seemed to be more effective; 5-year survival rates were 68%, 47%, and 21% for patients receiving a total dose of 53 Gy or higher, less than 53 Gy, and no radiation, respectively.⁴⁴ However, others have reported no prolongation of survival in irradiated patients.⁴⁷

A randomized trial of early versus delayed radiotherapy in adult patients was conducted by the European Organization for Research and Treatment of Cancer (EORTC). In this trial, patients with low-grade gliomas were randomly assigned to either (1) 54 Gy postoperative radiation; or (2) no immediate therapy. With a median follow-up of 5 years, the 5-year disease-free survival was better with immediate postoperative radiation (44% versus 37%; $P = 0.02$). However, the 5-year overall survival was the same (63% versus 66%) indicating that deferring the postoperative therapy can be an option for a selected group of patients.⁵¹ Recent followup of these patients showed that overall survival was not increased in patients who had received early radiotherapy (7.4 versus 7.2 years); however, seizures were controlled better in these patients.⁵² Although delaying radiation in young healthy patients without progressive neurologic decline can be controversial, there is a consensus to proceed with immediate postoperative radiation in older patients after a less-than-total resection, because their survival is as poor as patients with anaplastic astrocytoma. When radiation is deferred, regular follow-up is essential for patients receiving observation alone after resection.

When radiation is given to patients with low-grade astrocytomas, it is administered with restricted margins. Whole-brain RT (WBRT) results in more treatment-related neurotoxicity than does localized RT in these patients, who are often young and may survive for years. A T2-weighted MRI scan is the best means for evaluating tumor extent, because these tumors enhance weakly or not at all. The clinical target volume is defined by the T2-weighted tumor with a 1-2 cm margin. Every attempt should be made to decrease the radiation dose outside the target volume. Therefore, the use of only 2 parallel opposed portals is not recommended. A wedged pair beam is adequate for many lateral tumors. The dose outside the target can be further decreased by the use of multiple beams and 3-dimensional planning, and their use is encouraged. Stereotactic RT and intensity-modulated beams are being

studied at a few institutions, but their value is not known at present. The standard radiation dose for low-grade astrocytomas is 45 to 54 Gy, delivered in 1.8 to 2.0 Gy fractions. The selection of 45 to 54 Gy as the standard dose range is based on its relative safety when applied to a limited volume of the brain and on the lack of evidence for increased efficacy with higher doses.^{53,54} In a randomized trial conducted by the EORTC in patients with low-grade astrocytomas, no survival difference was observed when 45 Gy was compared with 59.4 Gy.⁵⁵ With a median follow-up of 6 years, the 5-year disease-free survival and the 5-year overall survival were the same. Patients were randomly assigned to receive either (1) 50.4 Gy in 28 fractions, or (2) 64.8 Gy in 36 fractions in another combined NCCTG (North Central Cancer Treatment Group), RTOG, and ECOG (Eastern Cooperative Oncology Group) study.⁵⁶ With a median follow-up of 6.3 years, the 5-year disease-free survival and the 5-year overall survival were again the same indicating that lower doses of RT are probably as effective as higher doses of radiation for low-grade gliomas. Enthusiasm for interstitial radiation or stereotactic radiosurgery in recurrent low-grade astrocytomas has decreased due to lack of evidence for efficacy.

Currently, temozolomide is an option (category 2B) in the treatment of low-grade gliomas; several agents (including temozolomide) are options at recurrence.⁵⁷ The RTOG conducted a clinical trial (9802) that allowed observation alone for completely resected low-grade gliomas in patients younger than 40 years and randomly assigned younger patients who were sub-totally resected and older patients who received any kind of resection to postoperative radiation to 54 Gy with or without PCV chemotherapy for 6 cycles. Preliminary results show that there was no increase in overall survival when adding PCV to RT.⁵⁸

Treatment Algorithm

When possible, maximal resection is recommended for low-grade astrocytomas, and the actual extent of resection should be documented

with an immediate postoperative MRI scan within 72 hours after surgery. For patients undergoing complete excision, observation alone is reasonable after the surgical intervention. These tumors tend to behave more aggressively in patients older than 45 years; therefore, immediate fractionated external beam RT is also an option for patients in this age group who have had complete excision. Chemotherapy can be considered (category 2B). Regular follow-up is essential for patients receiving observation alone after resection. Although surgery is generally recommended, serial observations are appropriate for selected patients.

Patients who only had a stereotactic biopsy, open biopsy, or subtotal excision are more likely to be treated with immediate fractionated external beam RT, especially if their symptoms are uncontrolled or progressive; chemotherapy (category 2B) is also an option. Because of concerns about the neurotoxicity of RT,⁵⁹ patients with residual asymptomatic low-grade astrocytoma may be followed until their disease progresses. Observation is also reasonable in patients with diffuse low-grade astrocytoma, because neurotoxicity increases with the size of the RT port required to encompass the entire lesion. Chemotherapy (category 2B) and fractionated external beam RT are other options.

Patients should be followed using MRI every 3 to 6 months for 5 years and then at least annually. At the time of recurrence, surgery is recommended for resectable lesions followed by chemotherapy if patients have previously had fractionated external beam RT. Reirradiation can follow chemotherapy, especially if progression-free survival is more than 2 years after prior RT, the new lesion is outside the target of previous RT, or the recurrence is small and geometrically favorable. Surgery can be followed by radiation, if it was not previously administered, or chemotherapy (category 2B for chemotherapy).

Oligodendrogliomas and Anaplastic Oligodendrogliomas

Oligodendrogliomas are thought to arise from oligodendrocytes, whereas mixed oligoastrocytomas probably develop from a common glial stem cell. Together, they account for less than 15% of all primary brain tumors.⁶⁰ Radiographically, the low-grade oligodendrogliomas appear well demarcated, occasionally contain calcifications, and do not enhance with contrast. The typical “fried egg” appearance of these tumors is evident in paraffin but not in frozen sections. Anaplastic oligodendrogliomas are characterized by high cellularity, nuclear pleomorphism, frequent mitosis, endothelial proliferation, and necrosis. On histopathologic assessment, these tumors can be confused with glioblastoma multiforme; however, 50% to 70% of low-grade oligodendrogliomas and anaplastic oligodendrogliomas have specific molecular genetic alterations (allelic losses of chromosomes 1p and 19q) that can help distinguish them from other types of gliomas.⁶¹

The median survival for patients with low-grade oligodendrogliomas is about 10 years; for anaplastic oligodendrogliomas, survival is about 3 to 5 years.⁶² Patients with mixed oligoastrocytomas tend to have the same outcome as patients with pure oligodendrogliomas.⁶³

Treatment Overview

Maximal feasible resection is preferred,⁶⁴ as previously noted for patients with low-grade astrocytomas. Gross total removal of these tumors is often possible, because most occur in the frontal lobes and because the tumors are frequently well demarcated.⁶⁵ Retrospective data have suggested that RT improves local control and survival.⁶⁶ Low-grade oligodendrogliomas and anaplastic oligodendrogliomas are chemosensitive tumors.⁶⁷⁻⁷⁰ Tumors with mixed oligoastrocytoma histology have a better prognosis than pure astrocytomas but not as good as pure oligodendrogliomas.

Treatment Algorithm

The treatment algorithm for patients with low-grade oligodendrogliomas is identical to the treatment algorithm for low-grade astrocytomas. Evidence is strong that gross total removal of the tumor leads to longer survival.^{64,65,71} The value of immediate postoperative radiation is still debated, because no randomized study has addressed this question. The largest retrospective study was conducted using patients with oligodendrogliomas registered by the Cancer Registry of Norway during a 25-year period.⁶² In this study involving 170 patients, survival was significantly longer in patients who received RT. However, the survival benefit was apparent only in the first 6 years of follow-up and only among patients who had less than a total surgical resection. The Mayo Clinic experience with oligodendrogliomas included 82 patients.⁶⁴ The survival of the 63 patients who received RT was comparable to the survival of the smaller group of 19 who underwent surgery only. However, the 2 patient groups were quite different, because the patients with poorer prognosis were referred for RT. When only patients who underwent a subtotal resection were compared, survival was prolonged with radiation.

For completely resected low-grade oligodendrogliomas, the consensus is postoperative radiation may be withheld if the patient is carefully followed; this is especially true for patients younger than 45 years. For patients with subtotally excised low-grade oligodendrogliomas, the considerations are the same as for patients with low-grade astrocytomas.

Three multicenter trials compared the results of RT for low-grade gliomas, including oligodendrogliomas, with either delaying the radiation until time of recurrence⁵¹ or using high-dose versus low-dose radiation.^{55,56} In these trials, 25% of the patients had oligodendrogliomas. Although time to progression was longer in the immediate therapy group in the EORTC study, progressing patients

whose RT had been delayed could be successfully salvaged, and survival was identical in both arms.⁵¹ In both the EORTC trial⁵⁵ and the intergroup randomized study,⁵⁶ no benefit of the high-dose RT compared to the low-dose RT delivered in identical fractionation was noted. However, more toxicity in the higher dose arm was documented. Therefore, the current recommended doses for low-grade oligodendrogliomas are in the range of 45 to 54 Gy (in 1.8-2.0 Gy fractions).⁵⁴ Delay of radiation for tumors in noneloquent regions and for small asymptomatic tumors in eloquent regions is a viable option based on current information.⁷² Because of the improved outcomes with the availability of improved mapping and surgical navigation techniques,⁷¹ an interdisciplinary approach⁷² based on institutional experience, expertise, and outcomes should be discussed frankly with each patient.

The radiation technique used for oligodendrogliomas is similar to the technique used for astrocytic gliomas. The occasional tendency of oligodendrogliomas to spread via the cerebrospinal fluid (CSF) does not justify the need for craniospinal radiation. Low-grade oligodendrogliomas and anaplastic oligodendrogliomas are considered to be chemosensitive brain tumors. Moreover, patients with these types of brain tumors who also have chromosomal loss of 1p or combined 1p19q loss in their tumors are more likely to respond to chemotherapy and have a better survival compared to other patients with oligodendrogliomas or anaplastic oligodendrogliomas who do not have these genetic alterations in their tumors.^{38,39,61,73} Therefore, chemotherapy is an option (category 2B) in these patients.

In the treatment algorithm for newly diagnosed low-grade oligodendrogliomas, recommendations include postoperative fractionated external beam RT, chemotherapy (category 2B), or observation (depending on age, extent of surgical resection, and symptoms). Surgery is generally recommended, but serial observations are appropriate for selected patients. Although chemotherapy is

traditionally reserved for tumor recurrence, chemotherapy (category 2B) may be an appropriate adjuvant therapy. However, there is a lack of prospective studies that define the role of chemotherapy in the treatment of oligodendrogliomas. There are no data, for example, showing that chemotherapy given up front along with radiation improves survival as opposed to reserving its use for when the tumor recurs. There are also no data to show that in these chemosensitive tumors it is reasonable to use chemotherapy alone postoperatively and to defer radiation until time of recurrence.

As with low-grade oligodendrogliomas, it is unclear how to best incorporate chemotherapy into the treatment strategy for anaplastic oligodendrogliomas and mixed anaplastic oligoastrocytomas. Results from an intergroup phase III randomized trial of PCV plus radiation versus radiation alone in anaplastic oligodendrogliomas and mixed anaplastic oligoastrocytomas showed there was no difference in median survival between patients who received PCV before radiation and those who received radiation alone.³⁸ A phase III trial from the EORTC found similar results.³⁹ However, patients with tumors demonstrating the 1p19q deletions lived longer with PCV plus RT treatment (7 versus 2.8 years, $P \leq .001$) in the intergroup study,³⁸ but this was not statistically significant in the EORTC study (40.3 versus 30.6 months, $P = .23$). The RTOG conducted a phase II study (RTOG 0131) of preradiation chemotherapy in patients with newly diagnosed anaplastic oligodendrogliomas and mixed anaplastic oligoastrocytomas. If a complete response was achieved after 6 cycles of temozolomide, then the patient was followed without radiation. If there was no complete response, then the patient was treated with radiation and concurrent temozolomide. Patients with 1p19q deletions who were treated with temozolomide and RT had better survival than those without the deletions.^{74,75} In summary, there are now specific chromosomal alterations that are powerful prognostic variables for patients with oligodendrogliomas and anaplastic oligodendrogliomas.

Patients whose tumors exhibit allelic loss of 1p and 19q have a better survival than patients whose tumors do not have these specific chromosomal alterations.

In terms of chemotherapy for newly diagnosed or recurrent oligodendrogliomas and anaplastic oligodendrogliomas, PCV has been most extensively studied; approximately 66% patients show responses to this chemotherapy regimen.^{67,76} However, because of PCV's toxicity, temozolomide is recommended for adjuvant treatment.⁷⁷ Temozolomide has been shown to produce a response rate (complete response and partial response) of 44% in patients with recurrent oligodendrogliomas and anaplastic oligodendrogliomas who had previously been treated with PCV.⁷⁸ A study found that temozolomide was effective in patients with progressive low-grade oligodendrogliomas; 51% of patients improved, especially those with uncontrolled epilepsy.⁷⁹

Ependymomas and Anaplastic Ependymomas

Ependymomas occur in both adults and children. In adults, approximately 33% of ependymomas arise infratentorially and 66% arise supratentorially; the opposite is true in children. These tumors can cause hydrocephalus and increased intracranial pressure, mimic brainstem lesions, cause multiple cranial nerve palsies, produce localizing cerebellar deficits, and cause neck stiffness and head tilt if they infiltrate the upper portion of the cervical cord.^{80,81}

Treatment Overview

Outcome is closely related to the extent of surgical resection. Patients with totally resected tumors tend to have the best prognosis. Even benign or low-grade ependymomas, if incompletely resected, have poor outcomes. RT significantly improves tumor control and survival. Survival at 5 years ranges from 33% to 80% in irradiated patients. Supratentorial ependymomas generally have a poorer prognosis than their infratentorial counterparts, because a greater proportion of

supratentorial lesions are of high grade and because larger volumes of residual disease tend to be present after surgical resection at this location.

The relatively low rate of neuraxis involvement and the equivalent outcome in series comparing local versus full craniospinal irradiation argue strongly for restricting the radiation volume to the posterior fossa in children with ependymomas.⁸² The uncertain implication of high histologic grade (or anaplastic ependymoma) similarly favors the use of local fields.⁸³ Based on dose-response analyses for ependymomas, the typical radiation dose is between 54-59.4 Gy locally using 1.8-2.0 Gy fractions.

For anaplastic ependymomas, researchers have recommended irradiating the entire craniospinal axis^{84,85} or administering WBRT, with an additional boost for high-grade supratentorial lesions located away from the CSF pathways, if leptomeningeal spread is not evident. However, studies have demonstrated that (1) local recurrence is the primary pattern of failure; (2) spinal seeding is uncommon in the absence of local failure; (3) the patterns of failure are similar in patients with high-grade tumors who are treated with local fields or craniospinal axis irradiation,^{82,83} and (4) spinal metastases may not be prevented by prophylactic treatment.^{82,85} As a result, the routine use of “prophylactic” craniospinal or WBRT does not appear to lead to improvement in survival.^{82,83,85} The 5-year overall survival rate for patients with grade II and III ependymomas who have received surgery and post-operative RT is about 70%.⁸⁶

The role of chemotherapy in the treatment of ependymomas is poorly defined. Although many drugs have been tried, ependymomas do not appear particularly responsive to chemotherapy. In children or adults with newly diagnosed ependymomas, no studies have demonstrated a survival advantage with chemotherapy plus irradiation, when compared with irradiation alone. However, chemotherapy is sometimes

considered as a salvage option to best supportive care or RT. Recurrence chemotherapy includes etoposide, temozolomide, nitrosourea, and platinum-based regimens.

Treatment Algorithm

The treatment algorithm for adult ependymomas revolves around histology, extent of surgical resection, and extent of disease in the craniospinal axis. Spine MRI should be delayed by at least 2 to 3 weeks after surgery to avoid post-surgical artifacts. Lumbar puncture for CSF analysis should be delayed at least 2 weeks after surgery to avoid possible false positive results; lumbar puncture may be contraindicated (for example, posterior fossa mass). For patients with a well-differentiated ependymoma who have undergone a gross total resection and have a negative screening spinal MRI scan, either limited-field or observation (only if supratentorial) fractionated external beam RT is recommended; RT or observation can be considered for infratentorial lesions. However, if a contrast-enhanced spinal MRI scan or CSF analysis reveals disease, craniospinal irradiation should be administered.

Patients with anaplastic ependymoma should also have a contrast enhanced brain and spinal MRI scan after a biopsy or subtotal resection. CSF analysis is recommended. If the MRI scan is negative, limited-field fractionated external beam RT is normally given. For limited fields, the clinical target volume (gross tumor volume plus 1-2 cm margin) should receive 54-59.4 Gy in 1.8 to 2.0 Gy fractions. However, if the spinal MRI scan or CSF analysis is positive, craniospinal irradiation is indicated. For craniospinal RT, whole brain and spine (to bottom of thecal sac) should receive 36 Gy in 1.8 fractions, followed by limited field to spine lesions to 45 Gy. The primary tumor site in the brain should receive a total dose of 54-59.4 Gy in 1.8-2.0 Gy fractions.

Follow-up of ependymoma depends on the extent and location of the disease. For localized disease, contrast-enhanced brain and spine MRI (if initially positive) should be done 2 to 3 weeks postoperatively and then every 3 to 4 months for 1 year. The interval can then be extended to every 4-6 months for year 2 and then every 6 to 12 months, depending on the physician's concern regarding the extent of disease, histology, and other relevant factors. If tumor recurrence in the brain or spine is noted on one of these scans, resection is recommended, if possible. Surgery should be followed with limited field external beam RT, if radiation was not given originally. If the recurrence is unresectable, radiation is a possible option if radiation was not given originally; consider reirradiation (including stereotactic radiosurgery if geometrically favorable). Chemotherapy should also be considered (because of anecdotal reports of response to chemotherapy) or best supportive care, depending on the histologic type, extent of disease, age of the patient, and PS. Radiation (including stereotactic radiosurgery if geometrically favorable) is considered another option for resectable recurrence.

Intraparenchymal Brain Metastases

Metastases to the brain are the most common intracranial tumors in adults and occur ten times more frequently than do primary brain tumors. As a result of advances in the diagnosis and treatment of metastatic brain lesions, most patients are helped by treatment and do not die of brain metastases. Brain metastases occur in 20% to 40% of adults with cancer and are most common in patients with cancers of the lung, breast, an unknown primary, and melanoma (see [NCCN Guidelines for Treatment of Cancer by Site](#)). For example, because therapy for metastatic breast cancer is improving, CNS involvement is becoming more common.⁸⁷ These lesions result from hematogenous metastases and are most common at the junction of the gray and white matter where the relatively narrow caliber of the blood vessels tends to

trap tumor emboli. More than 60% of patients with brain metastases also have lung lesions.

Most (80%) brain metastases occur in the cerebral hemispheres, an additional 15% occur in the cerebellum, and 5% occur in the brainstem. Approximately 80% of patients with brain metastases have a history of a systemic cancer, and 70% have multiple brain metastases evident on MRI scans.⁸⁸ The presenting signs and symptoms of metastatic brain lesions are similar to those of other mass lesions in the brain. The best diagnostic test is a contrast-enhanced MRI scan; however, not all brain lesions in patients with cancer are metastases.

Treatment Overview

Two randomized prospective studies assessed surgery plus WBRT compared with WBRT alone and found a dramatic difference in survival in patients with surgically accessible, single brain metastases. However, nearly 50% of these patients were not candidates for surgery because of the inaccessibility of the tumor, extensive systemic disease, or other factors. These patients and others with multiple brain metastases should receive either stereotactic radiosurgery or WBRT. After complete resection of a single metastatic lesion, WBRT decreases recurrences in the brain but does not improve survival.⁸⁹ Stereotactic radiosurgery can be used in the initial treatment of patients with only one or 2 appropriate brain metastases (that is, small, deep) or in those who relapse. The survival results can be comparable to those for surgical resection. There has never been a randomized trial comparing stereotactic radiosurgery with surgical resection. A multi-institutional retrospective analysis of stereotactic radiosurgery for solitary metastasis, which comes closest to addressing this issue,⁹⁰ showed median overall and functionally independent survival rates were 56 and 44 weeks respectively, indicating that the stereotactic radiosurgery is at least equivalent, if not superior to surgical resection. Chemotherapy is rarely used as primary therapy for brain metastases. Many tumors that

metastasize to the brain are not very chemosensitive (for example, non-small cell lung cancer, unknown primaries, melanoma) or have been already heavily pretreated with potentially effective agents. However, temozolomide may be useful in patients with previously untreated brain metastases from metastatic melanoma.^{91,92} Temozolomide given on a prolonged schedule plus thalidomide has been studied in patients with brain metastases; however, thromboembolic events can be a problem.⁹³⁻⁹⁵

Treatment Algorithm for Limited Metastatic Lesions

Patients who present with a single mass or multiple lesions suggestive of metastatic cancer to the brain, and do not have a known primary, require a careful systemic workup with chest x-ray or CT, abdominal or pelvic CT, or other tests as indicated.⁹⁶ FDG-PET can be considered if there are 2-3 lesions, and no primary has been found. If no other readily accessible tumor is available for biopsy, a stereotactic or open biopsy resection is indicated to establish a diagnosis. Among patients with a known history of cancer, if there are concerns regarding the diagnosis of CNS lesions, a stereotactic or open biopsy resection or subtotal resection is also needed. Surgical resection is limited to those with accessible tumors and limited systemic disease; whenever possible, principles of maximal safe resection are used. Patients with disseminated systemic disease who have poor systemic treatment options should be treated with WBRT rather than surgery; however, surgery should be considered to relieve mass effect. Solid brain metastases with systemic non-PCNS lymphoma are not well defined, but treatment may include systemic treatment, whole brain radiotherapy, or focal RT.

For patients with limited systemic disease or for whom reasonable systemic treatment options exist, aggressive management should be strongly considered. For resectable lesions, options include 1) surgery followed by WBRT (category 1 for 1 metastasis); 2) stereotactic

radiosurgery plus WBRT; (category 1 for 1 metastasis); or 3) stereotactic radiosurgery alone (category 2B).⁹⁷⁻⁹⁹ For unresectable disease, WBRT and/or radiosurgery can be used.^{90,100,101} The choice of therapy partly depends on the size of the lesion, whether the patient has symptoms, and institutional practice. The extent of surgery depends on the lesion's accessibility and the overall condition of the patient. For example, stereotactic radiosurgery may be used for a limited number of small (< 2 cm), deep, nonsymptomatic lesions; however, surgery may be more appropriate for larger, symptomatic lesions. Macroscopic total removal is the objective of surgery, given the studies demonstrating a survival benefit.¹⁰²

Although previously controversial, WBRT after a surgical resection of a single brain metastasis was shown to be useful by Patchell and colleagues (1998).⁸⁹ Their study randomly assigned patients to surgical resection alone compared with surgical resection and WBRT (50.4 Gy given in 28 fractions). Although the addition of WBRT to surgery decreased the incidence of CNS recurrence anywhere in the brain from 70% to 18% ($P < .001$), survival did not differ between the 2 treatment arms.⁸⁹ The use of WBRT after surgical or stereotactic radiosurgical treatment of single or multiple tumors appears to be less effective in preventing the development of new lesions in patients with radioresistant histologies (for example, melanoma, renal cell carcinoma, sarcoma) than in those patients with lung or breast adenocarcinoma (see [NCCN Guidelines for Treatment of Cancer by Site](#)). Patients with progressive extracranial disease whose survival is less than 3 months, should be treated with WBRT alone. A randomized study showed that surgical resection of a single lesion, followed by WBRT in patients with active systemic disease, did not improve survival compared with WBRT alone.⁹⁸

Patients should be followed with MRI every 3 months for 1 year and then as clinically indicated. Recurrence on radiograph can be

confounded by treatment effects. Strongly consider tumor tissue sampling if there is a high index of suspicion of recurrence. For patients with recurrent disease, prior therapy clearly influences the choice of further therapies. Patients with recurrent CNS disease should be assessed for local versus systemic disease, because therapy will differ. For local recurrences, patients who were previously treated with surgery can receive the following options: 1) surgery; 2) stereotactic radiosurgery; 3) WBRT; or 4) chemotherapy can be considered.¹⁰³ However, patients with local recurrences who previously received WBRT cannot receive WBRT again but can receive all of the other options. If the patient had previous stereotactic radiosurgery with a good response for greater than 6 months, then reconsider stereotactic radiosurgery if imaging supports active tumor and not necrosis. The algorithm for distant brain recurrences branches depending on whether patients have either 1-3 lesions or more than 3 lesions, although these are still considered to be limited lesions. WBRT should be used (30-45 Gy, given in 1.8 to 3.0 Gy fractions depending on the patient's PS) if this modality was not used for initial therapy.^{104,105} Local or systemic chemotherapy may be considered for select patients,¹⁰⁶ if the multiple lesions cannot be controlled by a combination of surgery and radiosurgery.¹⁰⁷

If systemic CNS disease progression occurs in the setting of limited systemic treatment options, WBRT (30-45 Gy, given in 1.8 to 3.0 Gy fractions) should be administered, if the patients have not been previously irradiated. Surgery should be considered to relieve mass effect.¹⁰⁷ For patients who have received prior WBRT, reirradiation is an option only if they had a positive response to the first course of RT treatment. Best supportive care is also an option.

Treatment Algorithm for Multiple Metastatic Lesions

Patients diagnosed with multiple (that is, >3) metastatic lesions should be treated with WBRT (30-45 Gy, given in 1.8 to 3.0 Gy fractions) with

or without stereotactic radiosurgery in selected cases (that is, limited number of lesions). For patients with poor neurologic performance, a more rapid course of RT can be considered (20 Gy, delivered in 5 fractions).¹⁰⁸ Palliative surgery should be considered if one lesion is causing a life-threatening mass effect, hemorrhage, or hydrocephalus. Occasionally, surgery has a role if one lesion is "dominant" and the patient is steroid dependent because of peritumoral edema and/or radiation necrosis.¹⁰⁷

After WBRT, patients should have a repeat contrast-enhanced MRI scan every 3 months for 1 year. If a recurrence is found, the algorithm branches depending on whether patients have (1) systemic disease progression with limited systemic treatment options; or (2) stable systemic disease or reasonable systemic treatment options. For patients with systemic disease progression, options include best supportive care or reirradiation. For patients with stable systemic disease, options include surgery, reirradiation, or chemotherapy.¹⁰⁹ The choice of chemotherapy depends on the primary tumor. For example, high-dose methotrexate can be used for CNS metastases from breast cancer,¹¹⁰ and topotecan can be used for metastases from lung cancer.

Neoplastic Meningitis

Neoplastic meningitis and leptomeningeal carcinomatosis refer to the multifocal seeding of the leptomeninges by malignant cells. Carcinomatous meningitis occurs when these cells originate from a solid tumor. When this is related to a systemic lymphoma, it is called lymphomatous meningitis.¹¹¹⁻¹¹³ Tumor cells gain access to the leptomeninges by hematogenous dissemination or by direct extension. Once these cells reach the CSF, they are disseminated throughout the neuraxis by the constant flow of CSF. The CSF travels from the ventricles through the foramen of Magendie and Luschka to the spinal canal and over the cortical convexities to the arachnoid granulations. Infiltration of the leptomeninges by any malignancy is a serious

complication that results in substantial morbidity and mortality. Neoplastic meningitis occurs in approximately 5% of patients with cancer. This disorder is being diagnosed with increasing frequency as patients live longer and as neuroimaging studies improve. The most common cancers to involve the leptomeninges are breast cancer, lung cancer, and melanoma. Without treatment, the median survival of patients diagnosed with this disorder is 4 to 6 weeks, with death resulting from progressive neurologic dysfunction.

The goals of treatment in patients with leptomeningeal metastases are to improve or stabilize the neurologic status of the patient and to prolong survival. Depending on whether patients are good or poor risk (see “Patient Stratification for Treatment”), therapy involves either 1) fractionated external beam RT to symptomatic sites of the neuraxis and to disease visible on neuroimaging studies or 2) intra-CSF chemotherapy (intrathecal [intralumbar] or intraventricular [intra-Ommaya]). Chemotherapy includes liposomal cytarabine,¹¹⁴ high-dose methotrexate,¹¹⁵ and thiotepa. These therapies increase the median survival to 3 to 6 months and often provide effective local control, allowing patients to die from systemic rather than neurologic complications of their neoplasm. Early diagnosis and therapy are critical to preserving neurologic function.

Patient Evaluation

Patients present with signs and symptoms ranging from injury to nerves that traverse the subarachnoid space, direct tumor invasion of the brain or spinal cord, alteration in the local blood supply, obstruction of normal CSF flow pathways leading to increased intracranial pressure, or interference with normal brain function. Patients should have a physical examination with a careful neurologic evaluation; MRI of the brain and spine should also be done, if intra-CSF chemotherapy is being considered. A definitive diagnosis is most commonly made by lumbar puncture if it is safe for the patient. The CSF protein is typically

increased, and there may be a pleocytosis or decreased glucose levels. The CSF cytology is positive approximately 50% of the time with the first lumbar puncture, and 85% of the time after 3 CSF examinations in patients who are ultimately proven to have neoplastic meningitis.

However, the CSF cytology is persistently negative in 10% to 15% of patients with leptomeningeal carcinomatosis. In these cases, (1) a suspicious CSF examination (for example, increased protein, low glucose, and/or a pleocytosis) combined with suggestive clinical findings (for example, multifocal neuraxis involvement, such as cranial nerve palsies and a lumbar radiculopathy that cannot be explained otherwise); and/or (2) suggestive radiologic features (for example, subarachnoid masses, diffuse contrast enhancement of the meninges, or hydrocephalus without a mass lesion) can be sufficient to treat when the patient is known to have a systemic malignancy. Although a positive CSF cytology in patients with solid tumors is virtually always diagnostic, reactive lymphocytes from infections (for example, herpes zoster infection) can often be mistaken for malignant lymphocytes.

Patient Stratification for Treatment

Once the diagnosis has been established, the patient's overall status should be carefully assessed to determine how aggressively the carcinomatous or lymphomatous meningitis should be treated. Unfortunately, this disease is most common in patients with advanced, treatment-refractory systemic malignancies for whom treatment options are limited. In general, fixed neurologic deficits (such as cranial nerve palsies or paraplegia) do not resolve with therapy, although encephalopathies may improve dramatically. As a result, patients should be stratified into “poor risk” and “good risk” groups. The poor-risk group includes patients with a low KPS; multiple, serious, major neurologic deficits; extensive systemic disease with few treatment options; bulky CNS disease; and neoplastic meningitis related to encephalopathy. The good-risk group includes patients with a high

KPS, no major neurologic deficits, minimal systemic disease, and reasonable systemic treatment options. Many patients fall in between these 2 groups, and clinical judgment will dictate how aggressive their treatment should be.

Treatment Algorithm for Neoplastic Meningitis

Patients in the poor-risk group are usually offered supportive care measures. Fractionated external beam RT to symptomatic sites (for example, to the whole brain for increased intracranial pressure or to the lumbosacral spine for a developing cauda equina syndrome) can be considered. If the patient stabilizes or improves, a more aggressive treatment approach may be considered. Patients with exceptionally chemosensitive tumors (for example, small cell lung cancer, lymphoma) may be treated.

Good-risk patients can receive fractionated external beam RT to symptomatic sites and to areas of bulky disease identified on neuroimaging studies. In addition, intrathecal or intraventricular (using a surgically implanted subcutaneous reservoir and ventricular catheter [SRVC]) chemotherapy can be administered. Initially, intrathecal chemotherapy is usually given by lumbar puncture, and the SRVC is placed later to administer the drugs more conveniently.

When dosing intrathecal chemotherapy for adults, no adjustment is made based on weight or body surface area. With methotrexate, thiotepa, and cytarabine, a typical dosing schedule is initially twice a week for 4 weeks; if the CSF cytology becomes negative, then continue with once-a-week administration of intrathecal chemotherapy for another 4 weeks, followed by once-a-month maintenance doses. Methotrexate (10-12 mg) is the drug most frequently used for intrathecal administration.¹¹⁶ Oral leucovorin (folinic acid) can be given (10 mg twice a day for 3 days starting the day of treatment) to reduce possible systemic toxicity without interfering with the efficacy of

methotrexate in the CSF. Intrathecal thiotepa (10 mg) can also be used in solid tumors, and cytarabine (50 mg) is often administered for lymphomatous meningitis. A depot form of cytarabine is now available that allows patients with lymphomatous meningitis to be treated every 2 weeks initially (rather than twice per week) followed by once-a-month maintenance treatment.^{114,117} In a randomized controlled trial, depot cytarabine was found to increase the time to neurologic progression, with a response rate comparable to methotrexate, while offering the benefit of a less demanding schedule of injection.¹¹⁴

If an SRVC is placed, a CSF flow scan should be strongly considered.^{118,119} CSF flow abnormalities are common in patients with neoplastic meningitis and often lead to increased intracranial pressure. Administering chemotherapy into the ventricle of a patient with a ventricular outlet obstruction increases the patient's risk for leukoencephalopathy. In addition, the agent administered will not reach the lumbar subarachnoid space where the original CSF cytology was positive. CSF flow scans are easily performed in most nuclear medicine departments. Indium 111-DTPA is administered into the SRVC, and imaging of the brain and spine is performed immediately after injection and then imaging is done again at 4 and 24 hours. If significant flow abnormalities are seen, fractionated external beam RT is administered to the sites of obstruction and a CSF flow scan is repeated. If CSF flow normalizes, which occurs most commonly in radiosensitive neoplasms, intrathecal chemotherapy commences. If significant flow abnormalities remain, then the patient should be treated as a poor-risk patient (that is, with supportive measures or RT).

For patients with a normal CSF flow scan and otherwise stable disease, induction intrathecal chemotherapy should be given for 4 to 6 weeks and then the patient should be reassessed clinically and with a repeat CSF cytology. Because the cytology is much less likely to be positive from the SRVC than from the lumbar subarachnoid space, it is critical

that it be sampled from the site where the cytology was originally positive. If the CSF cytology was originally negative, then reassess from the lumbar region. If the patient is clinically stable or improving and there is no clinical or radiologic evidence of progressive leptomeningeal disease, the patient should receive another month of “induction” intrathecal chemotherapy or should consider switching intrathecal drugs for 4 weeks. This regimen should be followed by 1 week per month of maintenance therapy if the cytology has converted to negative. The CSF cytology status should be followed every month.

Progressive Disease

The patient’s clinical and CSF status should be followed every 2 months. However, if the patient’s clinical status is deteriorating from progressive leptomeningeal disease or if the cytology is persistently positive, the clinician has 3 options: (1) RT to symptom sites; (2) chemotherapy; or (3) best supportive care.

Primary CNS Lymphoma

Primary CNS lymphoma is an aggressive form of non-Hodgkin’s lymphoma that develops within the brain, spinal cord, eye, or leptomeninges without evidence of systemic involvement.^{120,121} Overall, primary CNS lymphoma accounts for 0.5% to 2% of all primary brain tumors. However, its incidence has increased dramatically during the past 20 years in immunocompetent and immunocompromised patients.¹²² In immunocompetent primary CNS lymphoma patients, the mean age at diagnosis is 55 years; in immunocompromised patients, it is often younger (for example, 31 years in AIDS patients). These NCCN guidelines have been written for nonimmunosuppressed patients with primary CNS lymphoma.

Pathology

Pathologically, primary CNS lymphoma is a vasocentric neoplasm composed of a dense, monoclonal proliferation of lymphocytes that are

usually classified as large-cell or immunoblastic type and most often derive immunophenotypically from B cells.^{120,123} The tumor is infiltrative and typically extends beyond the primary lesion, as shown by CT or MRI scans, into regions of the brain with an intact blood-brain barrier. The brain parenchyma is involved in more than 90% of all primary CNS lymphoma patients, and the condition can be multifocal in more than 50% of cases.^{120,121,123,124}

Tumors are often periventricular and may involve ependymal lining cells or, if more peripherally located, may extend to the leptomeninges. Leptomeningeal involvement may remain localized to adjacent parenchymal sites or can be more diffuse (that is, positive cytology) in up to 30% of patients. Ocular involvement may develop independently in 10% to 20% of primary CNS lymphoma patients with primary brain disease. Less often, the tumor arises within the eye as the initial manifestation of primary CNS lymphoma. In rare cases, the spinal-cord parenchyma may be an initial or secondary site of primary CNS lymphoma.

Symptomatic Presentation

Patients with primary CNS lymphoma may present with various symptoms because of the multifocal nature of the disease. The most common complaint at diagnosis is a focal neurologic deficit (for example, hemiparesis, dysphasia), which occurs in more than 50% of all patients.^{120,121} Alterations of mental status (for example, loss of memory or confusion) and symptoms of increased intracranial pressure (for example, headache, nausea) are each noted in approximately 33% of patients. Seizure activity is less common and develops in 10% of patients. With ocular involvement, symptoms (blurred vision or floaters) develop in about 50% of patients. When the spinal cord is affected, patients complain of neck or back pain or they develop myelopathy.

Neuroradiologic evaluation is important to assist in the diagnosis of primary CNS lymphoma and to evaluate the effectiveness of subsequent therapy.^{120,124} On a CT scan, primary CNS lymphoma is usually isodense or hyperdense compared to the brain and enhances in most cases. With MRI, the tumor is often isointense or hypointense on T1- and T2-weighted images and enhances frequently. In some patients, however, the tumor does not enhance by CT or MRI scans, thus confusing and delaying the diagnosis.¹²⁵ It is also important to note that the imaging features of primary CNS lymphoma may be profoundly affected by prior use of steroids (for example, dexamethasone). Enhancement may be decreased or eliminated, and tumor volume may shrink dramatically.

Initial Evaluation

As previously mentioned, patients with primary CNS lymphoma can present with various symptoms and signs, including those associated with increased intracranial pressure, focal deficits, encephalopathy, and psychiatric alterations. CT of the chest, abdomen, and pelvis is recommended along with a chest x-ray. A body PET scan can be considered and can replace CT, bone marrow, and testicular ultrasound but data for use of PET in primary CNS lymphoma are lacking. Although primary CNS lymphoma often appears radiographically similar to other types of intracranial mass lesions, several CT and MRI features should raise the suspicion of lymphoma. These features include a periventricular distribution, ring enhancement, multiple lesions, and a smaller amount of edema than might otherwise be expected from a similar-sized metastatic tumor or glioma.

If, based on the MRI scan, there is a reasonably high suspicion of primary CNS lymphoma, it is preferable not to start therapy empirically with steroids prior to a diagnostic procedure unless medically indicated. In addition, a lumbar puncture with evaluation of CSF should be considered, if it can be done safely and without concern for herniation

from increased intracranial pressure. Although the CSF from these patients often contains a lymphocytosis, it is uncommon for the cytologist to see malignant lymphoid cells. Nevertheless, the yield for a positive diagnostic test can be increased by the use of molecular markers of monoclonality, such as an immunoglobulin gene rearrangement. If the CSF is negative, consider having patients undergo an ophthalmologic evaluation including a slit-lamp examination, to exclude an obvious malignant uveitis.

Despite CSF or uveal evaluation, the intracranial lesion often requires a brain biopsy for a definitive diagnosis.¹²⁶ Here again, use of immunohistochemistry to assess for monoclonality with gamma or kappa light chains and/or the use of molecular markers can be valuable in differentiating an inflammatory lesion from a malignant lymphoma. Even with these markers, however, a biopsy may occasionally be falsely negative, particularly if the patient had been treated previously with steroids. Thus, if a biopsy is nondiagnostic, we recommend that the steroids be tapered and the patient followed closely, both clinically and radiographically. If and when the lesion recurs, the lesion should be quickly re-biopsied before the initiation of steroids. If, on the other hand, a lesion is biopsied and no definitive diagnosis of lymphoma is made, and the patient does not have a history of steroid therapy, work-up for other diagnoses (for example, inflammatory processes) or rebiopsy is recommended.

Treatment Considerations

Steroid Administration

Steroids are cytolytic for primary CNS lymphomas and can significantly alter the appearance of these tumors on CT scans and MRI. It is recommended that steroids be withheld or used judiciously until diagnostic tissue can be obtained in patients suspected of having primary CNS lymphoma. Not only can steroids alter the CT scan or MRI target used by the surgeon (by decreasing enhancement and lesion

size), steroids may also affect the histologic appearance of tissue samples, preventing a definitive pathologic diagnosis.¹²³ The KPS can improve dramatically with steroids. Administration of steroids is appropriate if the patient has severely increased intracranial pressure and is in danger of herniation.

Stereotactic Biopsy

In contrast to the principles previously outlined for invasive astrocytomas and other gliomas, the surgical goals for primary CNS lymphoma are more modest and involve obtaining diagnostic tissue with minimal risk of morbidity and without a formal attempt at surgical resection.^{120,121,127-129} Currently, most authors recommend stereotactic biopsy as the surgical method of choice.¹²⁶ This approach stems from the fact that data do not demonstrate a survival advantage for patients who have had a complete resection or extensive subtotal resection when compared with those who have had only a stereotactic biopsy. In addition, aggressive resection has been associated with considerable risk for postoperative neurologic deficits.

Radiation Therapy

The role of RT for patients with primary CNS lymphoma continues to evolve. Early studies demonstrated that these tumors were radiosensitive and that complete and partial responses could be obtained using doses ranging from 3000 to 5000 cGy. However, the responses were brief, and patients often developed recurrent disease within a matter of months. These findings prompted the RTOG to design a dose-intensification study in which 41 patients with non-AIDS-related primary CNS lymphoma received 4000 cGy of WBRT plus a 2000-cGy boost to involved regions.¹²⁹ The median survival for the cohort was only 12.2 months, and tumors recurred frequently in the boosted field.

Similar limitations of efficacy for high-dose RT have been noted by DeAngelis (1995),¹²¹ as well as by other investigators.^{111,130,131}

Therefore, the currently recommended dose of RT for cerebral primary CNS lymphoma is between 24 and 36 Gy in 1.8 to 2.0 Gy fractions (whole brain), without a boost. However, RT may be withheld in patients older than 60 years to avoid toxicity. For patients with ocular lymphoma, RT is the treatment of choice. However, intraocular chemotherapy (category 2B) may also be effective (see “High-Dose Methotrexate”).

Chemotherapy

In general, methotrexate-based chemotherapy regimens are more effective against primary CNS lymphoma than non-methotrexate regimens.^{120,121,132} Most non-methotrexate protocols are based on the CHOP model and feature cyclophosphamide in combination with other drugs, usually doxorubicin, vincristine, and prednisone. Compared with methotrexate-based regimens, the progression-free and overall survival rates are lower in these non-methotrexate regimens, and they are often associated with an increased incidence of neurologic toxicity. The major reason cited for the decreased efficacy of CHOP and similar protocols is the poor penetration of the intact blood-brain barrier by cyclophosphamide and doxorubicin.

Timing of Radiotherapy and Chemotherapy

The major controversy regarding RT for primary CNS lymphoma involves the timing of treatment. Should it always be used as part of first-line therapy, in combination with chemotherapy, or should it be withheld in selected patients and not used until the time of recurrence? Although this issue has not been resolved, most authors recommend irradiation after some form of initial chemotherapy.^{108,120,121,127,129,133-135} A multicenter RTOG study demonstrated improved survival with the combination of chemotherapy, using high-dose methotrexate plus RT when compared with previous reports of RT alone; delayed neurotoxicity remains a risk of this approach.¹³⁶ Neuwelt and colleagues (1991) suggest withholding RT until recurrence or progression in all

patients to decrease the risk of radiation-related neuropsychological sequelae.¹²⁸ Others have similar recommendations but only for primary CNS lymphoma patients older than 50 years.^{121,137} DeAngelis and associates found that it was very uncommon for patients younger than 50 years to develop radiation-induced neurotoxicity.¹³⁶ However, WBRT can be deferred in older patients to decrease neurotoxicity.¹³²

The addition of chemotherapy has significantly improved disease-free and overall survival in patients with primary CNS lymphoma. With RT alone, median survival is approximately 12 months. When some form of chemotherapy has been added to the treatment regimen, median survival is extended; it ranges from 30 to 51 months.^{120,121,125,129,132,135,137} In many of these investigations, chemotherapy was administered before RT and often resulted in complete or partial responses.

Methotrexate appears to be the most effective drug and can be administered via the intravenous or intra-arterial route. Gabbai and associates (1989) reported a series of 13 patients given high-dose intravenous methotrexate before radiation.¹³³ They noted complete responses in 9 patients and partial responses in 4 patients, with an overall median survival of greater than 9 months. DeAngelis and colleagues also used preradiation methotrexate (intravenous and intrathecal) plus cytarabine in 31 patients with primary CNS lymphoma.¹²¹ The overall median survival for the cohort was 42.5 months, with partial responses in 17 patients and stable disease in 5 patients. Neuwelt and associates (1991) administered methotrexate via the intra-arterial route, in combination with osmotic blood-brain barrier disruption, cyclophosphamide, and procarbazine, to a series of 16 patients.¹²⁸ In all of these patients, irradiation was withheld until the time of disease progression (and was eventually administered to 9 of 16 patients). Chemotherapy induced complete responses in 13 patients and partial responses in 3 patients, with an over-all median survival of 44.5 months. Neuropsychological follow-up of the responding patients

who did not undergo irradiation demonstrated stable cognitive function. Gavrilovic and associates (2006) gave preradiation high-dose methotrexate (intravenous and intrathecal) along with vincristine, procarbazine, and consolidation cytarabine to 57 patients. Overall median survival was 51 months; survival was better for patients younger than 60 years at diagnosis.¹³²

Treatment Algorithm for CNS Lymphoma

Staging Workup

Once the diagnosis of primary CNS lymphoma is established, the patient should undergo a thorough staging workup. This workup involves a complete CNS evaluation including (if these tests have not previously been done) a slit-lamp eye examination, a lumbar puncture if possible, and a spinal MRI scan, particularly if the CSF is positive and/or the patient has symptoms referable to the spinal cord. An HIV blood test should also be performed, because both prognosis and treatment of patients with HIV-related primary CNS lymphoma might be different than that of patients who are otherwise immunocompetent. Relative to the staging workup for systemic disease, it is generally felt that a chest x-ray; CT of the chest, abdomen, and pelvis; physical examination; and complete blood work (including a complete blood count, platelets, liver function tests) are sufficient to rule out systemic involvement. It is very uncommon or rare for a patient to present with neurologic symptoms and to have a CNS lymphoma on biopsy and then ultimately be found to have an occult systemic lymphoma after more sensitive testing such as CT scans, gallium scans, or bone marrow biopsies (category 2B for biopsy only). Thus, these more elaborate tests are not necessary unless clinically indicated. Consider doing imaging such as testicular ultrasound for elderly men or body PET scans. Although body PET scan may replace CT, bone marrow, and testicular ultrasound, data for use of PET in primary CNS lymphoma are lacking.

Preradiation versus Postradiation Chemotherapy

Once the diagnosis of primary CNS lymphoma has been established and the extent of disease determined, treatment should be initiated as soon as possible. Preradiation chemotherapy, as opposed to postradiation chemotherapy, has been emphasized for several theoretical reasons. At least for agents such as methotrexate and cisplatin, some data (albeit in the pediatric literature) indicate that pre-radiation chemotherapy is less neurotoxic than postradiation chemotherapy. Additionally, drug delivery to a primary CNS lymphoma may be increased before radiation, when the blood-brain barrier is maximally disrupted by the tumor, than after RT, which results in tumor regression as well as partial repair and closure of the blood-brain barrier behind the regressing tumor. Finally, preradiation chemotherapy allows one to assess the efficacy of chemotherapy without the confounding variable of irradiation.

High-Dose Methotrexate

Several different chemotherapy regimens and agents have been used.^{128,129,132} High-dose methotrexate (≥ 3.5 g/m²) is the single most active agent against primary CNS lymphoma and should be a part of any chemotherapy regimen chosen to treat this disease. A series of phase I and phase II studies in the biomedical literature suggest that preradiation chemotherapy can prolong time to tumor progression and prolong median survival in patients treated with these agents, compared with radiation alone.¹³⁷ Most of the trials using preradiation chemotherapy, however, have demonstrated that elderly patients and/or patients who have an exceedingly poor KPS do not do well on chemotherapy.

Demographic Considerations

For healthier patients (that is, those with a KPS ≥ 40 and a creatinine clearance ≥ 50 mL/min), some type of preradiation chemotherapy is generally recommended; a high-dose methotrexate-based regimen is

most commonly used. Whether one performs WBRT after systemic chemotherapy depends on the responsiveness of the disease to chemotherapy (that is, whether a complete response occurs) and on the clinical judgment of the medical and radiation oncologists. WBRT may increase toxicity, especially in patients older than 60 years, and may be withheld in the primary setting.

If a patient is found to have malignant uveitis, radiation to the globe has been the standard recommendation because of poor penetration of systemic chemotherapy into the uveal fluid. However, there are reports of clearance of ocular lymphoma in patients who were treated with systemic high-dose methotrexate.¹³⁸ Therefore, with a primary CNS lymphoma patient who has asymptomatic ocular involvement, a reasonable strategy is to delay radiation to the globe in order to see if high-dose methotrexate is effective. Intraocular injection of chemotherapy (category 2B) is also an option. Additionally, if the patient is found to have a malignant pleocytosis in the CSF, direct intrathecal chemotherapy (either via a SRVC or by lumbar puncture) should be considered.

For patients with extremely poor KPS (<40) or moderate to severe renal dysfunction (creatinine clearance 50 mL/min or less), it is recommended that treatment consist of WBRT in order to rapidly induce a response, diminish neurologic morbidity, and optimize quality of life. Chemotherapy is also an option. If the lumbar puncture or spinal MRI is positive, consider intrathecal chemotherapy plus focal spinal RT for the few patients in this group who have an excellent response to WBRT and who achieve a reasonable quality of life with improved PS; systemic or intrathecal chemotherapy or re-irradiation could be considered when their disease recurs. For patients in this group who do not achieve a significant benefit from RT and whose disease progresses, palliative care is suggested (see [NCCN Palliative Care Guidelines](#)).

Progressive Disease

For patients who are treated with prior WBRT and ultimately relapse, treatment is re-irradiation or best supportive care; further chemotherapy (systemic or intrathecal) can be considered.

For patients who were initially treated with high-dose methotrexate based chemotherapy but did not receive RT, the decision about whether to use more chemotherapy or proceed to radiation at the time of relapse depends on the duration of response to initial chemotherapy. If a patient had experienced a relatively long-term response (that is, >1 year) with the first treatment regimen, then treating either with the same or another high-dose methotrexate-based regimen is reasonable.¹³² However, for patients who either have no response or relapse within a very short time after systemic chemotherapy, recommendations include WBRT or involved-field RT, with or without chemotherapy.¹³⁹ Alternative chemotherapeutic regimens should be considered for patients not suited for WBRT. Rituximab (anti-CD20 monoclonal antibody) and temozolomide are active in relapsed primary CNS lymphoma; these agents may be especially useful in older patients.¹⁴⁰⁻¹⁴³ Topotecan also is active and useful for patients who have failed methotrexate-based chemotherapy.^{144,145} The combination regimen of cisplatin, cytarabine, and dexamethasone is also useful.¹⁴⁶ Ultimately, the elucidation of the optimal chemotherapeutic regimen and the use of RT will depend on the results of clinical trials. Thus, all patients are encouraged to participate in clinical trials assessing improved treatments for this disease.

Metastatic Spinal Tumors

Metastatic spinal cord compression affects 5% to 14% of all patients with cancer (>20,000 cases are diagnosed each year in the United States).¹⁴⁷ The primary cancers causing spinal metastases are breast, lung, and prostate cancers; the thoracic spine is the most common site. Metastatic spinal tumors also include carcinomas of unknown origin

that metastasize to the spine. However, Pancoast (superior sulcus) tumors and primary sarcomas arising from the spine are excluded, because they are not considered to be metastatic spinal tumors. Spinal lesions are divided into 3 main categories based on the type of symptoms associated with the lesions.¹⁴⁸ The first category comprises patients with an incidental, asymptomatic metastatic lesion that can be observed with MRI follow-up in 2 to 3 months. However, biopsy and further treatment (that is, surgery, focal RT, or chemotherapy) of an incidental lesion are indicated if treatment of the patient as a whole is altered as a result of treatment of the incidental lesion. In the absence of symptoms, it is not mandatory to obtain a spinal MRI for every incidental metastatic lesion seen on surveillance bone scans. The second category involves severe, rapidly increasing back pain (including pain involving the cervical, thoracic, lumbar spine, or sacrum) attributable to the tumor. It can include mechanical or radicular types of pain. Increasing intensity, duration, and changes in the character of pain should trigger an evaluation with an MRI study, even in patients with pre-existing degenerative spine conditions. On the other hand, not every patient with minor, transient back pain and with a history of cancer needs an MRI. The third category involves neurologic symptoms including weakness, paresthesias, and bladder or bowel incontinence (constipation and diarrhea are not included)^{149,150}

A normal neurologic examination implies that there is no spinal radiculopathy or myelopathy correlating with the patient's symptoms. An abnormal neurologic examination includes motor abnormalities, sphincter abnormalities, and/or sensory deficits attributable to a dysfunction of nerve root(s) and/or the spinal cord. Therefore, presence of radiculopathy, myelopathy, or cauda equina syndrome is indicative of an abnormal examination. However, reflex asymmetry and/or presence of pathologic reflexes (Babinsky, Hoffman), as well as sensory deficits of a stocking/glove distribution are excluded as indicators of an abnormal examination. Patients with an abnormal neurologic

examination should receive steroids. The dose of steroids may vary (10-100 mg) with a recommended minimum dose of 4 mg of dexamethasone every 6 hours.¹⁵¹ A randomized trial supports the use of high-dose steroids.¹⁵² For patients with rapid neurologic deterioration or patients with significant myelopathy, an urgent noncontrast spinal MRI is recommended. Contrast can be used to highlight and further evaluate any focal abnormality. The MRI can be used to image the entire spine or a focal area of interest. If the patient is unable to have an MRI, then a CT myelogram is recommended.

Radiographic spinal cord compression implies deformation of the spinal cord because of epidural tumor, retropulsed bone fragment, or both.¹⁵¹ It should be noted that epidural tumor may occupy part of the spinal canal with or without partial obliteration of CSF around the spinal cord. Those cases do not qualify as radiographic spinal cord compression, because there is no cord deformation. For tumors occurring below L1, any canal compression of 50% or more should be considered of equal importance as spinal cord compression. Metastases to the spine without cord compression include the presence of tumor in the vertebral body, pedicle(s), lamina, transverse, or spinous process. It can also include epidural disease (without cord deformation).

In the presence of multiple metastatic spinal tumors, the one causing the patient's main symptoms is addressed first. Additional tumors can be treated at a later point according to the algorithm. In the event that no tumor is found on MRI, additional tests can be performed (for example, lumbar puncture if there is suspicion of neoplastic meningitis, electromyogram/nerve conduction [EMG/NC] studies for paraneoplastic conditions, or appropriate imaging to exclude a plexus tumor).

Because uniform criteria for spinal instability secondary to tumor do not currently exist, a consultation by a surgeon is recommended.¹⁵³ *Spinal instability* is grossly defined as the presence of significant kyphosis or

subluxation (deformity) or of significantly retropulsed bone fragment. Not every pathologic fracture implies spinal instability. The degree of kyphosis or subluxation compatible with instability depends on the location of the tumor in the spine and cannot be defined in absolute terms. The cross-sectional area of the vertebral body unaffected by the tumor and the patient's bone mineral density are additional factors affecting stability. In addition, vertebral body involvement is more important than dorsal element involvement with regard to stability. Circumferential disease as well as junctional and contiguous tumor location should be taken into account when assessing spinal stability.¹⁵⁴

Rapid neurologic deterioration is considered when the patient's neurologic examination is becoming worse on a daily basis and the patient's ambulatory status is threatened. This deterioration is particularly important if it occurs when the patient is already on a steroid regimen. Significant myelopathy implies presence of either a sensory level (that is, to pinprick) or loss of ambulatory status or bladder/bowel incontinence. Alternatively, a CT-guided biopsy of the spinal lesion can be performed for diagnostic purposes; however, in the presence of spinal cord compression, decompressive surgery should be considered as the best option for a patient with an unknown primary tumor.

For patients with spinal cord compression, strongly consider surgery if patients have spinal instability, no history of cancer, radioresistant tumors (for example, renal carcinoma, melanoma, sarcoma), rapid neurologic deterioration, previous RT, high cervical location, tumor is not lymphoma or myeloma, and/or for a single site epidural/spinal cord compression.^{149,155,156} Category 1 evidence supports the role of surgery for those willing to undergo surgery.¹⁵⁶ Surgery can involve tumor resection with or without spinal stabilization; surgery can be through an anterior, posterior, or a circumferential approach.¹⁵⁷ Spinal instrumentation is recommended if there is preoperative spinal instability or if instability is expected to occur after tumor resection.¹⁵²

Surgery also includes vertebroplasty/kyphoplasty, especially for patients with intractable pain.¹⁵⁸ It also includes implantation of a subarachnoid pump (morphine pump) for patients with intractable pain who are not candidates for tumor resection/stabilization or vertebroplasty/kyphoplasty. The “all others” category includes patients with compression but without evidence of spinal instability who have a radiation-sensitive tumor and a stable neurologic examination with a previously established histological diagnosis.¹⁵⁹ Short RT regimens over 2 to 3 weeks or less or consideration of stereotactic RT are options for these patients. Many fractionation schemes have been reported; the most common is a total of 30 Gy in 3-Gy daily fractions for 10 days.^{160,161} Note that nonambulatory patients with spinal cord compression who receive radiation alone have less chance of regaining their ability to walk than nonambulatory patients who receive surgery and radiation; however, many patients with spinal cord compression are not candidates for surgery.¹⁶¹ It is currently unclear whether surgery plus RT is better for selected patients or whether RT for patients with spinal instability produces worse outcomes.¹⁶² For patients with multiple myeloma or lymphoma with spinal cord compression, chemotherapy can be considered in lieu of RT.

Patients with slow-growing, symptomatic malignancies (for example, breast/renal carcinoma) or with solitary spinal metastases (especially if the original tumor has been resected) can alternatively be treated with surgery before RT. The role of newer forms of RT (for example, radiosurgery) in the treatment of metastatic spinal tumors needs to be defined, yet they should be considered for patients with recurrent tumors who have undergone prior surgery and conventional RT.

Intractable pain means either that pain is not controlled with oral analgesics or that the patient cannot tolerate the medication because of side effects. Intractable pain because of metastatic spinal tumor(s) can be treated by implantation of a subarachnoid pump, tumor

resection/stabilization, or vertebroplasty/kyphoplasty depending on stability, extent of disease, and location in the spinal column (see [NCCN Adult Cancer Pain Guidelines](#)).¹⁵²

Discussion
Update in
progress

References

1. American Cancer Society. Cancer Facts & Figures 2008. Atlanta: American Cancer Society; 2008.
(<http://www.cancer.org/downloads/STT/2008CAFFfinalsecured.pdf>).
2. Maher EA, McKee AC. Neoplasms of the central nervous system. In: Skarin AT, Canellos GP, eds. Atlas of Diagnostic Oncology, 3rd ed. London: United Kingdom; Elsevier Science Limited; 2003.
3. Sawaya R, Hammoud M, Schoppa D, et al. Neurosurgical outcomes in a modern series of 400 craniotomies for treatment of parenchymal tumors. *Neurosurgery* 1998;42:1044-1055.
4. Curran WJ, Scott CB, Horton J, et al. Recursive partitioning analysis of prognostic factors in three Radiation Therapy Oncology Group malignant glioma trials. *J Natl Cancer Inst* 1993;85:704-710.
5. Laws ER, Parney IF, Huang W, et al. Survival following surgery and prognostic factors for recently diagnosed malignant glioma: data from the Glioma Outcomes Project. *J Neurosurg* 2003;99:467-473.
6. Hentschel SJ, Sawaya R. Optimizing outcomes with maximal surgical resection of malignant gliomas. *Cancer Control* 2003;10:190-114.
7. Harsh GR 4th, Levin VA, Gutin PH, et al. Reoperation for recurrent glioblastoma and anaplastic astrocytoma. *Neurosurgery* 1987;21:615-621.
8. Walker MD, Alexander E, Hunt WE, et al. Evaluation of BCNU and/or radiotherapy in the treatment of anaplastic gliomas. *J Neurosurg* 1978;49:333-343.
9. Roa W, Brasher PM, Bauman G, et al. Abbreviated course of radiation therapy in older patients with glioblastoma multiforme: a prospective randomized clinical trial. *J Clin Oncol* 2004;22:1583-1588.
10. Souhami L, Seiferheld W, Brachman D, et al. Randomized comparison of stereotactic radiosurgery followed by conventional radiotherapy with carmustine to conventional radiotherapy with carmustine for patients with glioblastoma multiforme: report of Radiation Therapy Oncology Group 93-05 protocol. *Int J Radiat Oncol Biol Phys* 2004;60:853-860.
11. Laperriere NJ, Leung PM, McKenzie S, et al. Randomized study of brachytherapy in the initial management of patients with malignant astrocytoma. *Int J Radiat Oncol Biol Phys* 1998;41:1005-1011.
12. Walker MD, Green SB, Byar DP, et al. Randomized comparison of radiotherapy and nitrosoureas for the treatment of malignant glioma after surgery. *N Engl J Med* 1980;303:1323-1329.
13. Medical Research Council Brain Tumor Working Party. Randomized trial of procarbazine, lomustine, and vincristine in the adjuvant treatment of high-grade astrocytoma: a Medical Research Council trial. *J Clin Oncol* 2001;19:509-518.
14. Fine HA, Dear BG, Loeffler JS, et al. Meta-analysis of radiation therapy with and without adjuvant chemotherapy for malignant gliomas in adults. *Cancer* 1993;71:2585-2597.
15. Glioma Meta-analysis Trialists (GMT) Group. Chemotherapy for high-grade glioma. *Cochrane Database Syst Rev* 2002;(4):CD003913.
16. Stupp R, Mason WP, van den Bent MJ, et al. Radiotherapy plus concomitant and adjuvant temozolomide for glioblastoma. *N Engl J Med* 2005;352:987-996.
17. Hegi ME, Diserens AC, Gorlia T, et al. MGMT gene silencing and benefit from temozolomide in glioblastoma. *N Engl J Med* 2005;352:997-1003.
18. Mollemann M, Wolter M, Felsberg J, et al. Frequent promoter hypermethylation and low expression of the MGMT gene in oligodendroglial tumors. *Int J Cancer* 2005;113:379-385.
19. Glantz M, Chamberlain MC, Liu Q, et al. Temozolomide as an alternative to irradiation for elderly patients with newly diagnosed malignant gliomas. *Cancer* 2003;97:2262-2266.

20. Brandes AA, Vastola F, Basso U, et al. A prospective study on glioblastoma in the elderly. *Cancer* 2003;97:657-662.
21. Levin VA, Silva P, Hannigan J, et al. Superiority of postradiotherapy adjuvant chemotherapy with CCNU, procarbazine and vincristine (PCV) over BCNU for anaplastic glioma: NCOG 6G61 final report. *Int J Radiat Oncol Biol Phys* 1990;18:321-324.
22. Prados MD, Scott C, Curran WJ Jr, et al. Procarbazine, lomustine, and vincristine (PCV) chemotherapy for anaplastic astrocytoma: A retrospective review of radiation therapy oncology group protocols comparing survival with carmustine or PCV adjuvant chemotherapy. *J Clin Oncol* 1999;17:3389-3395.
23. Brandes AA, Tosoni A, Basso U, et al. Second-line chemotherapy with irinotecan plus carmustine in glioblastoma recurrent or progressive after first-line temozolomide chemotherapy: a phase II study of the Gruppo Italiano Cooperativo di Neuro-Oncologia (GICNO). *J Clin Oncol* 2004;22:4779-4786.
24. Reardon DA, Quinn JA, Vredenburgh J, et al. Phase II trial of irinotecan plus celecoxib in adults with recurrent malignant glioma. *Cancer* 2005;103:329-338.
25. Brandes AA, Basso U, Reni M, et al. First-line chemotherapy with cisplatin plus fractionated temozolomide in recurrent glioblastoma multiforme: A phase II study of the Gruppo Italiano Cooperativo di Neuro-Oncologia. *J Clin Oncol* 2004;22:1598-1604.
26. Vredenburgh JJ, Desjardins A, Herndon JE, II, et al. Bevacizumab plus irinotecan in recurrent glioblastoma multiforme. *J Clin Oncol* 2007;25(30):4722-4729.
27. Brem H, Piantadosi S, Burger PC, et al. Placebo-controlled trial of safety and efficacy of intraoperative controlled delivery by biodegradable polymers of chemotherapy for recurrent gliomas. *Lancet* 1995;345:1008-1012.
28. Valtonen S, Timonen U, Toivanen P, et al. Interstitial chemotherapy with carmustine-loaded polymers for high-grade gliomas: a randomized double-blind study. *Neurosurgery* 1997;41:44-48.
29. Westphal M, Hilt DC, Bortey E, et al. A phase 3 trial of local chemotherapy with biodegradable carmustine (BCNU) wafers (Gliadel wafers) in patients with primary malignant glioma. *Neuro-oncol* 2003;5:79-88.
30. Westphal M, Ram Z, Riddle V, et al; Executive Committee of the Gliadel Study Group. Gliadel wafer in initial surgery for malignant glioma: long-term follow-up of a multicenter controlled trial. *Acta Neurochir (Wien)* 2006;148(3):269-275; discussion 275. Epub 2006 Feb 17.
31. Fetell MR, Grossman SA, Fisher JD, et al. Preirradiation paclitaxel in glioblastoma multiforme: efficacy, pharmacology, and drug interactions. New Approaches to Brain Tumor Therapy Central Nervous System Consortium. *J Clin Oncol* 1997;15:3121-3128.
32. Grossman SA, Hochberg F, Fisher J, et al. Increased 9-aminocamptothecin dose requirements in patients on anticonvulsants. NABTT CNS Consortium. The New Approaches to Brain Tumor Therapy. *Cancer Chemother Pharmacol* 1998;42:118-126.
33. Kuhn JG. Influence of anticonvulsants on the metabolism and elimination of irinotecan. A North American Brain Tumor Consortium preliminary report. *Oncology (Huntingt)* 2002;16:33-40.
34. Crews KR, Stewart CF, Jones-Wallace D, et al. Altered irinotecan pharmacokinetics in pediatric high-grade glioma patients receiving enzyme-inducing anticonvulsant therapy. *Clin Cancer Res* 2002;8:2202-2209.
35. Vecht CJ, Wagner GL, Wilms EB. Interactions between antiepileptic and chemotherapeutic drugs. *Lancet Neurol* 2003;2:404-409.
36. Gilbert MR, Supko JG, Batchelor T, et al. Phase I clinical and pharmacokinetic study of irinotecan in adults with recurrent malignant glioma. *Clin Cancer Research* 2003;9:2940-2949.

37. Rowinsky EK. Paclitaxel pharmacology and other tumor types. *Semin Oncol* 1997;24:S19-1-S19-12.
38. Cairncross G, Berkey B, Shaw E, et al. Phase III trial of chemotherapy plus radiotherapy compared with radiotherapy alone for pure and mixed anaplastic oligodendroglioma: Intergroup Radiation Therapy Oncology Group Trial 9402. *J Clin Oncol* 2006;24:2707-2714.
39. van den Bent MJ, Carpentier AF, Brandes AA, et al. Adjuvant procarbazine, lomustine, and vincristine improves progression-free survival but not overall survival in newly diagnosed anaplastic oligodendrogliomas and oligoastrocytomas: a randomized European Organisation for Research and Treatment of Cancer phase III trial. *J Clin Oncol* 2006;24(18):2715-2722.
40. Yung WK, Prados MD, Yaya-Tur R, et al. Multicenter phase II trial of temozolomide in patients with anaplastic astrocytoma or anaplastic oligoastrocytoma at first relapse. *Temodal Brain Tumor Group. J Clin Oncol* 1999;17:2672-2771.
41. van den Bent MJ, Taphoorn MJ, Brandes AA, et al. Phase II study of first-line chemotherapy with temozolomide in recurrent oligodendroglial tumors: the European Organization for Research and Treatment of Cancer Brain Tumor Group Study 26791. *J Clin Oncol* 2003;21:2525-2528.
42. Silvani A, Eoli M, Salmaggi A, et al. Phase II trial of cisplatin plus temozolomide, in recurrent and progressive malignant glioma patients. *J Neurooncol* 2004;66(1-2):203-208.
43. Wick A, Felsberg J, Steinbach JP, et al. Efficacy and tolerability of temozolomide in an alternating weekly regimen in patients with recurrent glioma. *J Clin Oncol* 2007;25:3357-3361.
44. Shaw EG, Daumas-Duport C, Scheithauer BW, et al. Radiation therapy in the management of low-grade supratentorial astrocytomas. *J Neurosurg* 1989;70:853-861.
45. Keles GE, Lamborn KR, Berger MS. Low-grade hemispheric gliomas in adults: a critical review of extent of resection as a factor influencing outcome. *J Neurosurg* 2001;95:735-745.
46. Soffietti R, Chio A, Giordana MT, et al. Prognostic factors in well differentiated cerebral astrocytomas in the adult. *Neurosurgery* 1989;26:686-692.
47. Philippon JH, Clemençon SH, Fauchon FH, et al. Supratentorial low-grade astrocytomas in adults. *Neurosurgery* 1993;32:554-559.
48. Lo SS, Cho KH, Hall WA, et al. Does the extent of surgery have an impact on the survival of patients who receive postoperative radiation therapy for supratentorial low-grade gliomas? *Int J Cancer* 2001;96 (Suppl):71-78.
49. Kilic T, Ozduman K, Elmaci I, et al. Effect of surgery on tumor progression and malignant degeneration in hemispheric diffuse low-grade astrocytomas. *J Clin Neurosci* 2002;9:549-552.
50. Berger MS, Deliganis AVK, Dobbins J, et al. The effect of extent of resection on recurrence in patients with low grade cerebral hemisphere gliomas. *Cancer* 1994;74:1784-1791.
51. Karim AB, Afra D, Cornu P, et al. Randomized trial on the efficacy of radiotherapy for cerebral low-grade glioma in the adult: European Organization for Research and Treatment of Cancer Study 22845 with the Medical Research Council study BRO4: an interim analysis. *Int J Radiat Oncol Biol Phys* 2002;52:316-324.
52. van den Bent MJ, Afra D, de Witte O, et al. Long-term efficacy of early versus delayed radiotherapy for low-grade astrocytoma and oligodendroglioma in adults: the EORTC 22845 randomised trial. *Lancet* 2005;366(9490):985-990.
53. Shaw EG, Tatter SB, Lesser GJ, et al. Current controversies in the radiotherapeutic management of adult low-grade glioma. *Semin Oncol* 2004;31(5):653-658.
54. Shaw EG, Wisoff JH. Prospective clinical trials of intracranial low-grade glioma in adults and children. *Neuro Oncol* 2003;5(3):153-160.

55. Karim AB, Maat B, Hatlevoll R, et al. A randomized trial on dose-response in radiation therapy of low-grade cerebral glioma: European Organization for Research and Treatment of Cancer (EORTC) study 22844. *Int J Radiat Oncol Biol Phys* 1996;36:549-556.
56. Shaw E, Arusell R, Scheithauer B, et al. Prospective randomized trial of low- versus high-dose radiation therapy in adults with supratentorial low-grade glioma: Initial report of a North Central Cancer Treatment Group/ Radiation Therapy Oncology Group/ Eastern Cooperative Oncology Group study. *J Clin Oncol* 2002;20:2267-2276.
57. Quinn JA, Reardon DA, Friedman AH, et al. Phase II trial of temozolomide in patients with progressive low-grade glioma. *J Clin Oncol* 2003;21:646-651.
58. Shaw EG, Berkey B, Coons SW, et al. Initial report of Radiation Therapy Oncology Group (RTOG) 9802: Prospective studies in adult low-grade glioma (LGG). *J Clin Oncol (Meeting Abstracts)* 2006;24:1500.
59. Lo SS, Hall WA, Cho KH, et al. Radiation dose response for supratentorial low-grade glioma—institutional experience and literature review. *J Neurol Sci* 2003;214:43-48.
60. Nijjar TS, Simpson WJ, Gadalla T, et al. Oligodendroglioma: The Princess Margaret Hospital experience (1958-1984). *Cancer* 1993;71:4002-4006.
61. Cairncross JG, Ueki K, Zlatescu M, et al. Specific genetic predictors of chemotherapeutic response and survival in patients with anaplastic oligodendrogliomas. *J Natl Cancer Inst* 1998;90:1473-1479.
62. Lindegaard KF, Mork SJ, Eide GE, et al. Statistical analysis of clinicopathological features, radiotherapy, and survival in 170 cases of oligodendroglioma. *J Neurosurg* 1987;67:224-230.
63. Shaw EG, Scheithauer BW, O'Fallon JR, et al. Mixed oligoastrocytomas: A survival and prognostic factor analysis. *Neurosurgery* 1994;34:577-582.
64. Shaw EG, Scheithauer BW, O'Fallon JR, et al. Oligodendrogliomas: The Mayo Clinic experience. *J Neurosurg* 1992;76:428-434.
65. Mork SJ, Lindegaard KF, Halvorsen TB, et al. Oligodendroglioma: Incidence and biological behaviour in a defined population. *J Neurosurg* 1985;63:881-889.
66. Yeh SA, Lee TC, Chen HJ, et al. Treatment outcomes and prognostic factors of patients with supratentorial low-grade oligodendroglioma. *Int J Radiat Oncol Biol Phys* 2002;54:1405-1409.
67. Cairncross G, Macdonald D, Ludwin S, et al. Chemotherapy for anaplastic oligodendroglioma. *J Clin Oncol* 1994;12:2013-2021.
68. Buckner JC, Gesme D Jr, O'Fallon JR, et al. Phase II trial of procarbazine, lomustine, and vincristine as initial therapy for patients with low-grade oligodendroglioma or oligoastrocytoma: efficacy and associations with chromosomal abnormalities. *J Clin Oncol* 2003;21:251-255.
69. van den Bent M, Chinot OL, Cairncross JG. Recent developments in the molecular characterization and treatment of oligodendroglial tumors. *Neuro-oncol* 2003;5:128-138.
70. Ino Y, Betensky RA, Zlatescu MC, et al. Molecular subtypes of anaplastic oligodendroglioma: implications for patient management at diagnosis. *Clin Cancer Res* 2001;7:839-845.
71. Berger MS, Rostomily RC. Low grade gliomas: Functional mapping resection strategies, extent of resection and outcome. *J Neurooncol* 1997;34:85-101.
72. Buatti JM, Meeks SL, Ryken TC, et al. Low-grade gliomas: answering one question in a myriad of new questions [editorial]. *J Clin Oncol* 2002;20:2223-2224.
73. Smith JS, Perry A, Borell TJ, et al. Alterations of chromosome arms 1p and 19q as predictors of survival in oligodendrogliomas, astrocytomas, and mixed oligoastrocytomas. *J Clin Oncol* 2000;18:636-645.

74. Vogelbaum M, Berkey B, Peereboom D, et al. RTOG 0131: Phase II trial of pre-irradiation and concurrent temozolomide in patients with newly diagnosed anaplastic oligodendrogliomas and mixed anaplastic oligodendrogliomas [abstract]. *J Clin Oncol* 2005;23:1520.
75. Vogelbaum M, Berkey B, Peereboom D, et al. RTOG 0131: Phase II trial of pre-irradiation and concurrent temozolomide in patients with newly diagnosed anaplastic oligodendrogliomas and mixed anaplastic oligodendrogliomas: Relationship between 1p/19q status and progression-free survival [abstract]. *J Clin Oncol* 2006;24:1517.
76. van den Bent MJ. New perspectives for the diagnosis and treatment of oligodendroglioma. *Expert Rev Anticancer Ther* 2001;1:348-356.
77. van den Bent MJ. Advances in the biology and treatment of oligodendrogliomas. *Curr Opin Neurol* 2004;17(6):675-680.
78. Chinot O, Honore S, Dufour H, et al. Safety and efficacy of temozolomide in patients with recurrent anaplastic oligodendrogliomas after standard radiotherapy and chemotherapy. *J Clin Oncol* 2001;19:2449-2455.
79. Hoang-Xuan K, Capelle L, Kujas M, et al. Temozolomide as initial treatment for adults with low-grade oligodendrogliomas or oligoastrocytomas and correlation with chromosome 1p deletions. *J Clin Oncol* 2004;22:3133-3138.
80. De Vita VT, Hellman S, Rosenberg SA, eds. *Cancer: Principles and Practice of Oncology*, 7th ed. Philadelphia: JB Lippincott; 2004.
81. Packer RJ, Hoffman HJ, Friedman HS, et al. Tumors of the fourth ventricle. In: Levin VA, ed. *Cancer in the Nervous System*. New York: Churchill Livingstone 1996:153-156.
82. Vanuytsel LJ, Bessell EM, Ashley SE, et al. Intracranial ependymoma: Long-term results of a policy of surgery and radiotherapy. *Int J Radiat Oncol Biol Phys* 1992;23:313-319.
83. Goldwein JW, Corn BW, Finlay JL, et al. Is craniospinal irradiation required to cure children with malignant (anaplastic) intracranial ependymomas? *Cancer* 1991;67:2766-2771.
84. Wallner KE, Wara WM, Sheline GE, et al. Intracranial ependymomas: Results of treatment with partial or whole brain irradiation without spinal irradiation. *Int J Radiat Oncol Biol Phys* 1986;12:1937-1941.
85. Vanuytsel L, Brada M. The role of prophylactic spinal irradiation in localized intracranial ependymoma. *Int J Radiat Oncol Biol Phys* 1991;21:825.
86. Mansur DB, Perry A, Rajaram V, et al. Postoperative radiation therapy for grade II and III intracranial ependymoma. *Int J Radiat Oncol Biol Phys* 2005;61(2):387-391.
87. Lin NU, Bellon JR, Winer EP. CNS metastases in breast cancer. *J Clin Oncol* 2004;22:3608-3617.
88. DeVita VT, Jr., Hellman S, Rosenberg SA. *Principles & Practice of Oncology*, 6th Edition. January 2001. ISBN 0-7817-2229-2, Philadelphia: Lippincott Williams & Wilkins, 2000.
89. Patchell RA, Tibbs PA, Regine WF, et al. Postoperative radiotherapy in the treatment of single metastases to the brain: A randomized trial. *JAMA* 1998;280:1485-1489.
90. Auchter RM, Lamond JP, Alexander E, et al. A multi-institutional outcome and prognostic factor analysis of radiosurgery for resectable single brain metastasis. *Int J Radiat Oncol Biol Phys* 1996;35:27-35.
91. Agarwala SS, Kirkwood JM, Gore M, et al. Temozolomide for the treatment of brain metastases associated with metastatic melanoma: A phase II study. *J Clin Oncol* 2004;22:2101-2107.
92. Hofmann M, Kiecker F, Wurm R, et al. Temozolomide with or without radiotherapy in melanoma with unresectable brain metastases. *J Neurooncol* 2006;76(1):59-64.
93. Gajewski TF. Temozolomide for melanoma: new toxicities and new opportunities. *J Clin Oncol* 2004;22:580-581.
94. Krown SE, Niedzwiecki D, Hwu WJ, et al. Phase II study of temozolomide and thalidomide in patients with metastatic melanoma in

the brain: high rate of thromboembolic events (CALGB 500102). *Cancer* 2006;107(8):1883-1890.

95. Laber DA, Okeke RI, Arce-Lara C, et al. A phase II study of extended dose temozolomide and thalidomide in previously treated patients with metastatic melanoma. *J Cancer Res Clin Oncol* 2006;132(9):611-616. Epub 2006 Jun 2.

96. Weinberg JS, Lang FF, Sawaya R. Surgical management of brain metastases. *Curr Oncol Rep* 2001;3:476-483.

97. Patchell RA, Tibbs P, Walsh JW, et al. A randomized trial of surgery in the treatment of single brain metastases to the brain. *N Engl J Med* 1990;322:494-500.

98. Noordijk EM, Vecht CJ, Haaxma-Reiche H, et al. The choice of treatment of single brain metastasis should be based on extracranial tumor activity and age. *Int J Radiat Oncol Biol Phys* 1994;29:711-717.

99. Aoyama H, Shirato H, Tago M, et al. Stereotactic radiosurgery plus whole-brain radiation therapy vs stereotactic radiosurgery alone for treatment of brain metastases: A randomized controlled trial. *JAMA* 2006;295(21):2483-2491.

100. Bindal AK, Bindal RK, Hess KR, et al. Surgery versus radiosurgery in the treatment of brain metastasis. *J Neurosurg* 1996;84:748-754.

101. Andrews DW, Scott CB, Sperduto PW, et al. Whole brain radiation therapy with or without stereotactic radiosurgery boost for patients with one to three brain metastases: phase III results of the RTOG 9508 randomised trial. *Lancet* 2004;363(9422):1665-1672.

102. Lang FF, Wildrick DM, Sawaya R. Management of cerebral metastases: the role of surgery. *Cancer Control* 1998;5:124-129.

103. Shaw E, Scott C, Souhami L, et al. Single dose radiosurgical treatment of recurrent previously irradiated primary brain tumors and brain metastases: final report of RTOG protocol 90-05. *J Radiat Oncol Biol Phys* 2000;47(2):291-298.

104. Tsao MN, Lloyd NS, Wong RK, et al; Supportive Care Guidelines Group of Cancer Care Ontario's Program in Evidence-based Care. Radiotherapeutic management of brain metastases: a systematic review and meta-analysis. *Cancer Treat Rev* 2005;31(4):256-273.

105. Eichler AF, Loeffler JS. Multidisciplinary management of brain metastases. *The Oncologist* 2007;12:884-898.

106. van den Bent MJ. The role of chemotherapy in brain metastases. *Eur J Cancer* 2003;39:2114-2120.

107. Lang FF, Chang EL, Abi-Said D, et al. Metastatic brain tumors. In: Winn HR, ed. *Youman's Neurological Surgery*, 5th ed. Philadelphia: Saunders; 2004:1077-1097.

108. Borgelt B, Gelber R, Kramer S, et al. The palliation of brain metastases: Final results of the first two studies by the Radiation Therapy Oncology Group. *Int J Radiat Oncol Biol Phys* 1980;6:1-9.

109. Alexander E, Moriarty TM, Davis RB, et al. Stereotactic radiosurgery for the definitive, noninvasive treatment of brain metastases. *J Natl Cancer Inst* 1995;87:34-40.

110. Lassman AB, Abrey LE, Shah GD, et al. Systemic high-dose intravenous methotrexate for central nervous system metastases. *J Neurooncol* 2006;78(3):255-260.

111. Jayson GC, Howell A. Carcinomatous meningitis in solid tumors. *Ann Oncol* 1996;7:773-786.

112. Chamberlain MC. Carcinomatous meningitis. *Arch Neurol* 1997;54:16-17.

113. Grossman SA, Krabak ML. Leptomeningeal carcinomatosis. *Cancer Treat Rev* 1999;25:103-119.

114. Jaeckle KA, Phuphanich S, Bent MJ, et al. Intrathecal treatment of neoplastic meningitis due to breast cancer with a slow-release formulation of cytarabine. *Br J Cancer* 2001;84(2):157-163.

115. Bokstein F, Lossos A, Lossos IS, et al. Central nervous system relapse of systemic non-Hodgkin's lymphoma: results of treatment based on high-dose methotrexate combination chemotherapy. *Leuk Lymphoma* 2002;43(3):587-593.
116. Glantz MJ, Cole BF, Recht L, et al. High-dose intravenous methotrexate for patients with nonleukemic leptomeningeal cancer: Is intrathecal chemotherapy necessary? *J Clin Oncol* 1998;16:1561-1567.
117. Glantz MJ, LaFollette S, Jaeckle KA, et al. Randomized trial of a slow-release vs a standard formulation of cytarabine for the intrathecal treatment of lymphomatous meningitis. *J Clin Oncol* 1999;17:3110-3116.
118. Glantz MJ, Hall WA, Cole BF, et al. Diagnosis, management of, and survival of patients with leptomeningeal cancer based on cerebrospinal fluid-flow status. *Cancer* 1995;75:2919-2931.
119. Chamberlain MC, Kormanik PR. Carcinomatous meningitis secondary to breast cancer: Predictors of response to combined modality therapy. *J Neurooncol* 1997;35:55-64.
120. Fine HA, Mayer RJ. Primary central nervous system lymphoma. *Ann Intern Med* 1993;119:1093-1104.
121. DeAngelis LM. Current management of primary central nervous system lymphoma. *Oncology* 1995;9:63-71.
122. Coté TR, Manns A, Hardy CR, et al. Epidemiology of brain lymphoma among people with or without acquired immunodeficiency syndrome. *J Natl Cancer Inst* 1996;88:675-679.
123. Traweek ST. Nervous system involvement by lymphoma, leukemia and other hematopoietic cell proliferations. In: Bigner DD, McLendon RE, Bruner JM, eds. *Russell & Rubinstein's Pathology of Tumors of the Nervous System*. 6th ed. London, Arnold Press, 1998:195-237.
124. Johnson BA, Fram EK, Johnson PC, et al. The variable MR appearance of primary lymphoma of the central nervous system: Comparison with histopathologic features. *Am J Neuroradiol* 1997;18:563-572.
125. DeAngelis LM. Cerebral lymphoma presenting as a nonenhancing lesion on computed tomographic/magnetic resonance scan. *Ann Neurol* 1993;33:308-311.
126. Abrey LE, Batchelor TT, Ferreri AJ, et al; International Primary CNS Lymphoma Collaborative Group. Report of an international workshop to standardize baseline evaluation and response criteria for primary CNS lymphoma. *J Clin Oncol* 2005;23(22):5034-5043. Epub 2005 Jun 13.
127. DeAngelis LM, Yahalom J, Heinemann MH, et al. Primary CNS lymphoma: Combined treatment with chemotherapy and radiotherapy. *Neurology* 1990;40:80-86.
128. Neuwelt EA, Goldman DL, Dahlborg SA, et al. Primary CNS lymphoma treated with osmotic blood-brain barrier disruption: Prolonged survival and preservation of cognitive function. *J Clin Oncol* 1991;9:1580-1590.
129. Nelson DF, Martz KL, Bonner H, et al. Non-Hodgkin's lymphoma of the brain: Can high dose, large volume radiation therapy improve survival? Report on a prospective trial by the Radiation Therapy Oncology Group (RTOG): RTOG 8315. *Int J Radiat Oncol Biol Phys* 1992;23:9-17.
130. Chamberlain MC, Corey-Bloom J. Leptomeningeal metastases: 111-Indium-DTPA CSF flow studies. *Neurology* 1991;41:1765-1769.
131. Grossman SA, Moynihan TJ. Neoplastic meningitis. *Neurol Clin N Am* 1991;9:843-856.
132. Gavriloic IT, Hormigo A, Yahalom J, et al. Long-term follow-up of high-dose methotrexate-based therapy with and without whole brain irradiation for newly diagnosed primary CNS lymphoma. *J Clin Oncol* 2006;24(28):4570-4574.
133. Gabbai AA, Hochberg FH, Linggood RM, et al. High-dose methotrexate for non-AIDS primary central nervous system lymphoma. Report of 13 cases. *J Neurosurg* 1989;70:190-194.

134. Hiraga S, Arita N, Ohnishi T, et al. Rapid infusion of high-dose methotrexate resulting in enhanced penetration into cerebrospinal fluid and intensified tumor response in primary central nervous system lymphomas. *J Neurosurg* 1999;91:221-230.
135. DeAngelis LM. Primary central nervous system lymphomas. *Curr Treat Options Oncol* 2001;2:309-318.
136. DeAngelis LM, Seiferheld W, Schold SC, et al. Combination chemotherapy and radiotherapy for primary central nervous system lymphoma: Radiation Therapy Oncology Group Study 93-10. *J Clin Oncol* 2002;20:4643-4648.
137. Freilich RJ, Delattre JY, Monjour A, et al. Chemotherapy without radiation therapy as initial treatment for primary CNS lymphoma in older patients. *Neurology* 1996;46:435-439.
138. Batchelor T, Carson K, O'Neill A, et al. Treatment of primary CNS lymphoma with methotrexate and deferred radiotherapy: a report of NABTT 96-07. *J Clin Oncol* 2003;21:1044-1049.
139. Nguyen PL, Chakravarti A, Finkelstein DM, et al. Results of whole-brain radiation as salvage of methotrexate failure for immunocompetent patients with primary CNS lymphoma. *J Clin Oncol* 2005;23:1507-1513.
140. Wong ET, Tishler R, Barron L, et al. Immunochemotherapy with rituximab and temozolomide for central nervous system lymphomas. *Cancer* 2004;101:139-145.
141. Enting RH, Demopoulos A, DeAngelis LM, et al. Salvage therapy for primary CNS lymphoma with a combination of rituximab and temozolomide. *Neurology* 2004;63:901-903.
142. Hoang-Xuan K, Camilleri-Broet S, Soussain C. Recent advances in primary CNS lymphoma. *Curr Opin Oncol* 2004b;16:601-606.
143. Pitini V, Baldari S, Altavilla G, et al. Salvage therapy for primary central nervous system lymphoma with (90)Y-Ibritumomab and Temozolomide. *Neurooncol* 2007 Jul;83(3):291-293. Epub 2007 Jan 24.
144. Voloschin AD, Betensky R, Wen PY, et al. Topotecan as salvage therapy for relapsed or refractory primary central nervous system lymphoma. *J Neurooncol* 2008;86(2):211-215. Epub 2007 Sep 21.
145. Younes A, Preti HA, Hagemester FB, et al. Paclitaxel plus topotecan treatment for patients with relapsed or refractory aggressive non-Hodgkin's lymphoma. *Ann Oncol* 2001;12(7):923-927.
146. Martelli M, Vignetti M, Zinzani PL, et al. High-dose chemotherapy followed by autologous bone marrow transplantation versus dexamethasone, cisplatin, and cytarabine in aggressive non-Hodgkin's lymphoma with partial response to front-line chemotherapy: a prospective randomized Italian multicenter study. *J Clin Oncol* 1996;14(2):534-542.
147. Nelson KA, Walsh D, Abdullah O, et al. Common complications of advanced cancer. *Semin Oncol* 2000;27:34-44.
148. Ruckdeschel J. Spinal cord compression: problems common to cancer and its therapy: Part II. In: Abeloff M, Armitage J, Lichter A, eds. *Clinical Oncology*. New York: Churchill Livingstone, 1995;36:811-819.
149. Zerick W, Fessler R, Cahill D. Metastatic spine tumors: an overview. In: Rea GL, ed. *Spine Tumors*. American Association of Neurological Surgeons, 1994:7-23.
150. York J, Wildrick D, Gokaslan Z. Metastatic tumors. In: Benzel EC, Stillerman CB, eds. *The Thoracic Spine*. St. Louis, MO: Quality Medical Publishing, Inc, 1999:392-411.
151. Vrionis FD, Miguel R. Management of spinal metastases. *Seminars in Pain Medicine* 2003;1:25-33.
152. Sørensen PS, Helweg-Larsen S, Mouridsen H, et al. Effect of high-dose dexamethasone in carcinomatous metastatic spinal cord compression treated with radiotherapy: a randomised trial. *1994;30:22-27*.
153. Sundaresan N, Steinberger A, Moore F, et al. Surgical management of primary metastatic tumors of the spine. In: Schmidek HH. *Operative Neurosurgical Techniques: Indications, Methods, and*

Results, 4th ed, Vol 2. Philadelphia: W. B. Saunders Company, 2000;2146-2170.

154. Vrionis FD, Small J. Surgical management of metastatic spinal neoplasms. *Neurosurg Focus* 2003;15:E12.

155. Wang JC, Boland P, Mitra N, et al. Single-stage posterolateral transpedicular approach for resection of epidural metastatic spine tumors involving the vertebral body with circumferential reconstruction: Results in 140 patients. *J Neurosurg Spine* 2004;1:287-298.

156. Patchell RA, Tibbs PA, Regine WF, et al. Direct decompressive surgical resection in the treatment of spinal cord compression by metastatic cancer: a randomized trial. *Lancet* 2005;366:643-648.

157. Gokaslan Z, York J, Walsh G, et al. Transthoracic vertebrectomy for metastatic spinal tumors. *J Neurosurg* 1998;89:599-609.

158. Fourney DR, Schomer DE, Nader R, et al. Percutaneous vertebroplasty and kyphoplasty for painful vertebral body fractures in cancer patients. *J Neurosurg* 2003;98:21-30.

159. Siegal T, Siegal T. Surgical management of malignant epidural tumors compressing the spinal cord. In: Schmidek HH. *Operative Neurosurgical Techniques: Indications, Methods, and Results*, 4th ed, Vol 2. Philadelphia: W. B. Saunders Company, 2000;2171-2197.

160. Rades D, Stalpers LJ, Veninga T, et al. Evaluation of five radiation schedules and prognostic factors for metastatic spinal cord compression. *J Clin Oncol* 2005;23(15):3366-3375.

161. Kwok Y, Regine WF, Patchell RA. Radiation therapy alone for spinal cord compression: Time to improve upon a relatively ineffective status quo. *J Clin Oncol* 2005;23:1-3.

162. Loblaw DA, Perry J, Chambers A, et al. Systematic review of the diagnosis and management of malignant extradural spinal cord compression: the Cancer Care Ontario Practice Guidelines Initiative's Neuro-Oncology Disease Site Group. *J Clin Oncol* 2005;23:2028-2037.

Discussion
update in
progress